

GEORGIAN MEDICAL NEWS

ISSN 1512-0112

No 1 (310) Январь 2021

ТБИЛИСИ - NEW YORK



ЕЖЕМЕСЯЧНЫЙ НАУЧНЫЙ ЖУРНАЛ

Медицинские новости Грузии
საქართველოს სამედიცინო სიახლენი

GEORGIAN MEDICAL NEWS

No 1 (310) 2021

Published in cooperation with and under the patronage
of the Tbilisi State Medical University

Издается в сотрудничестве и под патронажем
Тбилисского государственного медицинского университета

გამოიცემა თბილისის სახელმწიფო სამედიცინო უნივერსიტეტთან
თანამშრომლობითა და მისი პატრონაჟით

ЕЖЕМЕСЯЧНЫЙ НАУЧНЫЙ ЖУРНАЛ
ТБИЛИСИ - НЬЮ-ЙОРК

GMN: Georgian Medical News is peer-reviewed, published monthly journal committed to promoting the science and art of medicine and the betterment of public health, published by the GMN Editorial Board and The International Academy of Sciences, Education, Industry and Arts (U.S.A.) since 1994. **GMN** carries original scientific articles on medicine, biology and pharmacy, which are of experimental, theoretical and practical character; publishes original research, reviews, commentaries, editorials, essays, medical news, and correspondence in English and Russian.

GMN is indexed in MEDLINE, SCOPUS, PubMed and VINITI Russian Academy of Sciences. The full text content is available through EBSCO databases.

GMN: Медицинские новости Грузии - ежемесячный рецензируемый научный журнал, издаётся Редакционной коллегией и Международной академией наук, образования, искусств и естествознания (IASEIA) США с 1994 года на русском и английском языках в целях поддержки медицинской науки и улучшения здравоохранения. В журнале публикуются оригинальные научные статьи в области медицины, биологии и фармации, статьи обзорного характера, научные сообщения, новости медицины и здравоохранения.

Журнал индексируется в MEDLINE, отражён в базе данных SCOPUS, PubMed и ВИНТИ РАН. Полнотекстовые статьи журнала доступны через БД EBSCO.

GMN: Georgian Medical News – საქართველოს სამედიცინო სიახლენი – არის ყოველთვიური სამეცნიერო სამედიცინო რეცენზირებადი ჟურნალი, გამოიცემა 1994 წლიდან, წარმოადგენს სარედაქციო კოლეგიისა და აშშ-ის მეცნიერების, განათლების, ინდუსტრიის, ხელოვნებისა და ბუნებისმეტყველების საერთაშორისო აკადემიის ერთობლივ გამოცემას. GMN-ში რუსულ და ინგლისურ ენებზე ქვეყნდება ექსპერიმენტული, თეორიული და პრაქტიკული ხასიათის ორიგინალური სამეცნიერო სტატიები მედიცინის, ბიოლოგიისა და ფარმაციის სფეროში, მიმოხილვითი ხასიათის სტატიები.

ჟურნალი ინდექსირებულია MEDLINE-ის საერთაშორისო სისტემაში, ასახულია SCOPUS-ის, PubMed-ის და ВИНТИ РАН-ის მონაცემთა ბაზებში. სტატიების სრული ტექსტი ხელმისაწვდომია EBSCO-ს მონაცემთა ბაზებშიდან.

МЕДИЦИНСКИЕ НОВОСТИ ГРУЗИИ

Ежемесячный совместный грузино-американский научный электронно-печатный журнал
Агентства медицинской информации Ассоциации деловой прессы Грузии,
Международной академии наук, индустрии, образования и искусств США.
Издается с 1994 г., распространяется в СНГ, ЕС и США

ГЛАВНЫЙ РЕДАКТОР

Николай Пирцхалаишвили

НАУЧНЫЙ РЕДАКТОР

Елене Гиоргадзе

ЗАМЕСТИТЕЛЬ ГЛАВНОГО РЕДАКТОРА

Нино Микаберидзе

НАУЧНО-РЕДАКЦИОННЫЙ СОВЕТ

Зураб Вадачкориа - председатель Научно-редакционного совета

Михаил Бахмутский (США), Александр Геннинг (Германия), Амиран Гамкрелидзе (Грузия),
Константин Кипиани (Грузия), Георгий Камкамидзе (Грузия),
Паата Куртанидзе (Грузия), Вахтанг Масхулия (Грузия),
Тенгиз Ризнис (США), Реваз Сепиашвили (Грузия), Дэвид Элуа (США)

НАУЧНО-РЕДАКЦИОННАЯ КОЛЛЕГИЯ

Константин Кипиани - председатель Научно-редакционной коллегии

Архимандрит Адам - Вахтанг Ахаладзе, Амиран Антадзе, Нелли Антелава, Тенгиз Асатиани,
Гия Берадзе, Рима Бериашвили, Лео Бокерия, Отар Герзмава, Лиана Гогиашвили, Нодар Гогебашвили,
Николай Гонгадзе, Лия Дваладзе, Тамар Долиашвили, Манана Жвания, Тамар Зерекидзе,
Ирина Квачадзе, Нана Квирквелия, Зураб Кеванишвили, Гурам Кикнадзе, Димитрий
Кордзаиа, Теймураз Лежава, Нодар Ломидзе, Джанлуиджи Мелотти, Марина Мамаладзе,
Караман Пагава, Мамука Пирцхалаишвили, Анна Рехвиашвили, Мака Сологашвили, Рамаз Хецуриани,
Рудольф Хохенфеллнер, Кахабер Челидзе, Тинатин Чиковани, Арчил Чхотуа,
Рамаз Шенгелия, Кетеван Эбралидзе

Website:

www.geomednews.org

The International Academy of Sciences, Education, Industry & Arts. P.O.Box 390177,
Mountain View, CA, 94039-0177, USA. Tel/Fax: (650) 967-4733

Версия: печатная. **Цена:** свободная.

Условия подписки: подписка принимается на 6 и 12 месяцев.

По вопросам подписки обращаться по тел.: 293 66 78.

Контактный адрес: Грузия, 0177, Тбилиси, ул. Асатиани 7, IV этаж, комната 408
тел.: 995(32) 254 24 91, 5(55) 75 65 99

Fax: +995(32) 253 70 58, e-mail: ninomikaber@geomednews.com; nikopir@geomednews.com

По вопросам размещения рекламы обращаться по тел.: 5(99) 97 95 93

© 2001. Ассоциация деловой прессы Грузии

© 2001. The International Academy of Sciences,
Education, Industry & Arts (USA)

GEORGIAN MEDICAL NEWS

Monthly Georgia-US joint scientific journal published both in electronic and paper formats of the Agency of Medical Information of the Georgian Association of Business Press; International Academy of Sciences, Education, Industry and Arts (USA).
Published since 1994. Distributed in NIS, EU and USA.

EDITOR IN CHIEF

Nicholas Pirtskhalaishvili

SCIENTIFIC EDITOR

Elene Giorgadze

DEPUTY CHIEF EDITOR

Nino Mikaberidze

SCIENTIFIC EDITORIAL COUNCIL

Zurab Vadachkoria - Head of Editorial council

Michael Bakhmutsky (USA), Alexander Gënning (Germany),
Amiran Gamkrelidze (Georgia), David Elua (USA),
Konstantin Kipiani (Georgia), Giorgi Kamkamidze (Georgia), Paata Kurtanidze (Georgia),
Vakhtang Maskhulia (Georgia), Tengiz Riznis (USA), Revaz Sepiashvili (Georgia)

SCIENTIFIC EDITORIAL BOARD

Konstantin Kipiani - Head of Editorial board

Archimandrite Adam - Vakhtang Akhaladze, Amiran Antadze, Nelly Antelava,
Tengiz Asatiani, Gia Beradze, Rima Beriashvili, Leo Bokeria, Kakhaber Chelidze,
Tinatin Chikovani, Archil Chkhotua, Lia Dvaladze, Tamar Doliashvili, Ketevan Ebralidze,
Otar Gerzmava, Liana Gogiashvili, Nodar Gogebashvili, Nicholas Gongadze,
Rudolf Hohenfellner, Zurab Kevanishvili, Ramaz Khetsuriani, Guram Kiknadze,
Dimitri Kordzaia, Irina Kvachadze, Nana Kvirkvelia, Teymuraz Lezhava, Nodar Lomidze, Marina
Mamaladze, Gianluigi Melotti, Kharaman Pagava, Mamuka Pirtskhalaishvili,
Anna Rekhviashvili, Maka Sologhashvili, Ramaz Shengelia, Tamar Zerekidze, Manana Zhvania

CONTACT ADDRESS IN TBILISI

GMN Editorial Board
7 Asatiani Street, 4th Floor
Tbilisi, Georgia 0177

Phone: 995 (32) 254-24-91
995 (32) 253-70-58
Fax: 995 (32) 253-70-58

CONTACT ADDRESS IN NEW YORK

NINITEX INTERNATIONAL, INC.
3 PINE DRIVE SOUTH
ROSLYN, NY 11576 U.S.A.

Phone: +1 (917) 327-7732

WEBSITE

www.geomednews.org

К СВЕДЕНИЮ АВТОРОВ!

При направлении статьи в редакцию необходимо соблюдать следующие правила:

1. Статья должна быть представлена в двух экземплярах, на русском или английском языках, напечатанная через **полтора интервала на одной стороне стандартного листа с шириной левого поля в три сантиметра**. Используемый компьютерный шрифт для текста на русском и английском языках - **Times New Roman (Кириллица)**, для текста на грузинском языке следует использовать **AcadNusx**. Размер шрифта - **12**. К рукописи, напечатанной на компьютере, должен быть приложен CD со статьей.

2. Размер статьи должен быть не менее десяти и не более двадцати страниц машинописи, включая указатель литературы и резюме на английском, русском и грузинском языках.

3. В статье должны быть освещены актуальность данного материала, методы и результаты исследования и их обсуждение.

При представлении в печать научных экспериментальных работ авторы должны указывать вид и количество экспериментальных животных, применявшиеся методы обезболивания и усыпления (в ходе острых опытов).

4. К статье должны быть приложены краткое (на полстраницы) резюме на английском, русском и грузинском языках (включающее следующие разделы: цель исследования, материал и методы, результаты и заключение) и список ключевых слов (key words).

5. Таблицы необходимо представлять в печатной форме. Фотокопии не принимаются. **Все цифровые, итоговые и процентные данные в таблицах должны соответствовать таковым в тексте статьи**. Таблицы и графики должны быть озаглавлены.

6. Фотографии должны быть контрастными, фотокопии с рентгенограмм - в позитивном изображении. Рисунки, чертежи и диаграммы следует озаглавить, пронумеровать и вставить в соответствующее место текста **в tiff формате**.

В подписях к микрофотографиям следует указывать степень увеличения через окуляр или объектив и метод окраски или импрегнации срезов.

7. Фамилии отечественных авторов приводятся в оригинальной транскрипции.

8. При оформлении и направлении статей в журнал МНГ просим авторов соблюдать правила, изложенные в «Единых требованиях к рукописям, представляемым в биомедицинские журналы», принятых Международным комитетом редакторов медицинских журналов - <http://www.spinesurgery.ru/files/publish.pdf> и http://www.nlm.nih.gov/bsd/uniform_requirements.html В конце каждой оригинальной статьи приводится библиографический список. В список литературы включаются все материалы, на которые имеются ссылки в тексте. Список составляется в алфавитном порядке и нумеруется. Литературный источник приводится на языке оригинала. В списке литературы сначала приводятся работы, написанные знаками грузинского алфавита, затем кириллицей и латиницей. Ссылки на цитируемые работы в тексте статьи даются в квадратных скобках в виде номера, соответствующего номеру данной работы в списке литературы. Большинство цитированных источников должны быть за последние 5-7 лет.

9. Для получения права на публикацию статья должна иметь от руководителя работы или учреждения визу и сопроводительное отношение, написанные или напечатанные на бланке и заверенные подписью и печатью.

10. В конце статьи должны быть подписи всех авторов, полностью приведены их фамилии, имена и отчества, указаны служебный и домашний номера телефонов и адреса или иные координаты. Количество авторов (соавторов) не должно превышать пяти человек.

11. Редакция оставляет за собой право сокращать и исправлять статьи. Корректур авторам не высылаются, вся работа и сверка проводится по авторскому оригиналу.

12. Недопустимо направление в редакцию работ, представленных к печати в иных издательствах или опубликованных в других изданиях.

При нарушении указанных правил статьи не рассматриваются.

REQUIREMENTS

Please note, materials submitted to the Editorial Office Staff are supposed to meet the following requirements:

1. Articles must be provided with a double copy, in English or Russian languages and typed or computer-printed on a single side of standard typing paper, with the left margin of 3 centimeters width, and 1.5 spacing between the lines, typeface - **Times New Roman (Cyrillic)**, print size - 12 (referring to Georgian and Russian materials). With computer-printed texts please enclose a CD carrying the same file titled with Latin symbols.

2. Size of the article, including index and resume in English, Russian and Georgian languages must be at least 10 pages and not exceed the limit of 20 pages of typed or computer-printed text.

3. Submitted material must include a coverage of a topical subject, research methods, results, and review.

Authors of the scientific-research works must indicate the number of experimental biological species drawn in, list the employed methods of anesthetization and soporific means used during acute tests.

4. Articles must have a short (half page) abstract in English, Russian and Georgian (including the following sections: aim of study, material and methods, results and conclusions) and a list of key words.

5. Tables must be presented in an original typed or computer-printed form, instead of a photocopied version. **Numbers, totals, percentile data on the tables must coincide with those in the texts of the articles.** Tables and graphs must be headed.

6. Photographs are required to be contrasted and must be submitted with doubles. Please number each photograph with a pencil on its back, indicate author's name, title of the article (short version), and mark out its top and bottom parts. Drawings must be accurate, drafts and diagrams drawn in Indian ink (or black ink). Photocopies of the X-ray photographs must be presented in a positive image in **tiff format**.

Accurately numbered subtitles for each illustration must be listed on a separate sheet of paper. In the subtitles for the microphotographs please indicate the ocular and objective lens magnification power, method of coloring or impregnation of the microscopic sections (preparations).

7. Please indicate last names, first and middle initials of the native authors, present names and initials of the foreign authors in the transcription of the original language, enclose in parenthesis corresponding number under which the author is listed in the reference materials.

8. Please follow guidance offered to authors by The International Committee of Medical Journal Editors guidance in its Uniform Requirements for Manuscripts Submitted to Biomedical Journals publication available online at: http://www.nlm.nih.gov/bsd/uniform_requirements.html
http://www.icmje.org/urm_full.pdf

In GMN style for each work cited in the text, a bibliographic reference is given, and this is located at the end of the article under the title "References". All references cited in the text must be listed. The list of references should be arranged alphabetically and then numbered. References are numbered in the text [numbers in square brackets] and in the reference list and numbers are repeated throughout the text as needed. The bibliographic description is given in the language of publication (citations in Georgian script are followed by Cyrillic and Latin).

9. To obtain the rights of publication articles must be accompanied by a visa from the project instructor or the establishment, where the work has been performed, and a reference letter, both written or typed on a special signed form, certified by a stamp or a seal.

10. Articles must be signed by all of the authors at the end, and they must be provided with a list of full names, office and home phone numbers and addresses or other non-office locations where the authors could be reached. The number of the authors (co-authors) must not exceed the limit of 5 people.

11. Editorial Staff reserves the rights to cut down in size and correct the articles. Proof-sheets are not sent out to the authors. The entire editorial and collation work is performed according to the author's original text.

12. Sending in the works that have already been assigned to the press by other Editorial Staffs or have been printed by other publishers is not permissible.

**Articles that Fail to Meet the Aforementioned
Requirements are not Assigned to be Reviewed.**

ავტორთა საქურაღებოლ!

რედაქციაში სტატიის წარმოდგენისას საჭიროა დაიცვათ შემდეგი წესები:

1. სტატია უნდა წარმოადგინოთ 2 ცალად, რუსულ ან ინგლისურ ენებზე დაბეჭდილი სტანდარტული ფურცლის 1 გვერდზე, 3 სმ სიგანის მარცხენა ველისა და სტრიქონებს შორის 1,5 ინტერვალის დაცვით. გამოყენებული კომპიუტერული შრიფტი რუსულ და ინგლისურენოვან ტექსტებში - **Times New Roman (Кириллица)**, ხოლო ქართულენოვან ტექსტში საჭიროა გამოვიყენოთ **AcadNusx**. შრიფტის ზომა – 12. სტატიას თან უნდა ახლდეს CD სტატიით.

2. სტატიის მოცულობა არ უნდა შეადგენდეს 10 გვერდზე ნაკლებს და 20 გვერდზე მეტს ლიტერატურის სიის და რეზიუმეების (ინგლისურ, რუსულ და ქართულ ენებზე) ჩათვლით.

3. სტატიაში საჭიროა გაშუქდეს: საკითხის აქტუალობა; კვლევის მიზანი; საკვლევი მასალა და გამოყენებული მეთოდები; მიღებული შედეგები და მათი განსჯა. ექსპერიმენტული ხასიათის სტატიების წარმოდგენისას ავტორებმა უნდა მიუთითონ საექსპერიმენტო ცხოველების სახეობა და რაოდენობა; გაუტკივარებისა და დაძინების მეთოდები (მწვავე ცდების პირობებში).

4. სტატიას თან უნდა ახლდეს რეზიუმე ინგლისურ, რუსულ და ქართულ ენებზე არანაკლებ ნახევარი გვერდის მოცულობისა (სათაურის, ავტორების, დაწესებულების მითითებით და უნდა შეიცავდეს შემდეგ განყოფილებებს: მიზანი, მასალა და მეთოდები, შედეგები და დასკვნები; ტექსტუალური ნაწილი არ უნდა იყოს 15 სტრიქონზე ნაკლები) და საკვანძო სიტყვების ჩამონათვალი (key words).

5. ცხრილები საჭიროა წარმოადგინოთ ნაბეჭდი სახით. ყველა ციფრული, შემაჯამებელი და პროცენტული მონაცემები უნდა შეესაბამებოდეს ტექსტში მოყვანილს.

6. ფოტოსურათები უნდა იყოს კონტრასტული; სურათები, ნახაზები, დიაგრამები - დასათაურებული, დანომრილი და სათანადო ადგილას ჩასმული. რენტგენოგრამების ფოტოასლები წარმოადგინეთ პოზიტიური გამოსახულებით **tiff** ფორმატში. მიკროფოტოსურათების წარწერებში საჭიროა მიუთითოთ ოკულარის ან ობიექტივის საშუალებით გადიდების ხარისხი, ანათალების შედეგის ან იმპრეგნაციის მეთოდი და აღნიშნოთ სურათის ზედა და ქვედა ნაწილები.

7. სამამულო ავტორების გვარები სტატიაში აღინიშნება ინიციალების თანდართვით, უცხოურისა – უცხოური ტრანსკრიპციით.

8. სტატიას თან უნდა ახლდეს ავტორის მიერ გამოყენებული სამამულო და უცხოური შრომების ბიბლიოგრაფიული სია (ბოლო 5-8 წლის სიღრმით). ანბანური წყობით წარმოდგენილ ბიბლიოგრაფიულ სიაში მიუთითეთ ჯერ სამამულო, შემდეგ უცხოელი ავტორები (გვარი, ინიციალები, სტატიის სათაური, ჟურნალის დასახელება, გამოცემის ადგილი, წელი, ჟურნალის №, პირველი და ბოლო გვერდები). მონოგრაფიის შემთხვევაში მიუთითეთ გამოცემის წელი, ადგილი და გვერდების საერთო რაოდენობა. ტექსტში კვადრატულ ფხიხლებში უნდა მიუთითოთ ავტორის შესაბამისი N ლიტერატურის სიის მიხედვით. მიზანშეწონილია, რომ ციტირებული წყაროების უმეტესი ნაწილი იყოს 5-6 წლის სიღრმის.

9. სტატიას თან უნდა ახლდეს: ა) დაწესებულების ან სამეცნიერო ხელმძღვანელის წარდგინება, დამოწმებული ხელმოწერითა და ბეჭდით; ბ) დარგის სპეციალისტის დამოწმებული რეცენზია, რომელშიც მითითებული იქნება საკითხის აქტუალობა, მასალის საკმაობა, მეთოდის სანდოობა, შედეგების სამეცნიერო-პრაქტიკული მნიშვნელობა.

10. სტატიის ბოლოს საჭიროა ყველა ავტორის ხელმოწერა, რომელთა რაოდენობა არ უნდა აღემატებოდეს 5-ს.

11. რედაქცია იტოვებს უფლებას შეასწოროს სტატია. ტექსტზე მუშაობა და შეჯერება ხდება საავტორო ორიგინალის მიხედვით.

12. დაუშვებელია რედაქციაში ისეთი სტატიის წარდგენა, რომელიც დასაბეჭდად წარდგენილი იყო სხვა რედაქციაში ან გამოქვეყნებული იყო სხვა გამოცემებში.

აღნიშნული წესების დარღვევის შემთხვევაში სტატიები არ განიხილება.

Содержание:

Taner Demirci, Hasret Cengiz, Sedat Cetin, Ceyhun Varim, Gizem Karatas Kılıçcıoğlu MYELOLIPOMA COEXISTENCE WITH GLUCOCORTICOID AND ANDROGEN SECRETING ADRENOCORTICAL CARCINOMA: SLOW AND BENIGN CLINICAL COURSE.....	7
Русин В.И., Русин В.В., Горленко Ф.В., Добош В.М., Лопит М.М. ИЗОЛИРОВАННАЯ ПРОФУНДОПЛАСТИКА (ДИФФЕРЕНЦИРОВАННЫЙ ВЫБОР).....	11
Зубач О.Б., Григорьева Н.В., Поворозник В.В. 10-ЛЕТНЯЯ ЛЕТАЛЬНОСТЬ У ПАЦИЕНТОВ ПОСЛЕ ПЕРЕЛОМОВ ПРОКСИМАЛЬНОГО ОТДЕЛА БЕДРЕННОЙ КОСТИ.....	19
Zenaishvili M., Japaridze Sh., Tushishvili A., Davitashvili O., Kevanishvili Z. STUTTERING: INITIATING FACTORS, EVOLUTION, HEALING PERSPECTIVES.....	23
Hirna H., Kostyshyn I., Rozhko M., Levandovskiy R., Nakashidze G. ANALYSIS OF IMMUNE CHANGES AND THEIR ROLE IN THE DEVELOPMENT OF ORAL AND OROPHARYNGEAL CANCER	29
Tsitadze T., Puturidze S., Lomidze T., Margvelashvili V., Kalandadze M. PREVALENCE AND RISK-FACTORS OF BRUXISM IN CHILDREN AND ADOLESCENT POPULATION AND ITS IMPACT ON QUALITY OF LIFE (REVIEW).....	36
Solovyeva Z., Zaporozhskaya-Abramova E., Adamchik A., Gushchin A., Risovanniy S., Manukyan I. COMPARATIVE EVALUATION OF THE CLINICAL EFFICACY OF MODERN REMINERALIZING DRUGS IN THE TREATMENT OF ENAMEL CARIES (FOCAL DEMINERALIZATION)	39
Bakradze A., Vadachkoria Z., Kvachadze I. ELECTROPHYSIOLOGICAL CORRELATES OF MASTICATORY MUSCLES IN NASAL AND ORONASAL BREATHING MODES	45
Borysenko A., Timokhina T., Kononova O. INDICATORS OF LOCAL IMMUNITY IN THE COMORBID COURSE OF CARIES AND GASTROESOPHAGEAL REFLUX DISEASE.....	48
Dolidze K., Margvelashvili V., Nikolaishvili M., Suladze T., Pkhaladze M. STUDY OF THE HYGIENIC CHARACTERISTICS OF THE ORAL CAVITY UNDER THE COMPLEX EFFECT OF PHOTODYNAMIC THERAPY AND TSKALTUBO SPRING WATER RADON HORMESIS.....	54
Танская О.А., Островский Ю.П., Курлянская Е.К., Валентюкевич А.В., Колядко М.Г. ОСНОВНЫЕ КРИТЕРИИ ОТБОРА ПАЦИЕНТОВ ПРИ ФОРМИРОВАНИИ ЛИСТА ОЖИДАНИЯ НА ТРАНСПЛАНТАЦИЮ СЕРДЦА	60
Yelshibayeva E., Dautov T., Rakhimzhanova R., Gutberlet M., Mardenkyzy D., Kozhakhmetova Zh., Saduakasova A. COMPUTED TOMOGRAPHY IN DETECTING FEATURES OF CORONARY ATHEROSCLEROSIS IN DIFFERENT ETHNIC GROUPS OF KAZAKHSTAN POPULATION.....	68
Podzolkov V., Safronova T., Nebieridze N., Loriya I., Cherepanov A. TRANSFORMING GROWTH FACTOR AND ARTERIAL STIFFNESS IN PATIENTS WITH UNCONTROLLED ARTERIAL HYPERTENSION	77
Gvasalia T., Kvachadze I., Giorgobiani T. SENSITIVITY TO MECHANICAL PAIN BASED ON SATIETY LEVELS IN WOMEN	83
Povoroznyuk V., Nishkumay O., Lazarieva K., Lazarev P. FEATURES OF BONE METABOLISM AND THEIR INFLUENCE ON ARTERIAL WALL STIFFNESS IN POSTMENOPAUSAL WOMEN WITH CONTROLLED UNCOMPLICATED HYPERTENSION	87
Solomonina N., Vacharadze K., Mgvdeladze G. CHARACTERISTICS OF DRUG RESISTANT TUBERCULOSIS IN GEORGIA (2015-2020).....	93

Abramidze T., Gotua M., Bochorishvili E., Melikidze N., Gamkrelidze A. CYPRESS POLLEN SENSITIZATION IN GEORGIA: CLINICAL AND MOLECULAR CHARACTERISTICS.....	101
Притыко Н.Г., Коваленко О.Е. ОСОБЕННОСТИ МОЗГОВОЙ ГЕМОДИНАМИКИ У ПАЦИЕНТОВ С СИНДРОМОМ ХРОНИЧЕСКОЙ ЦЕРЕБРАЛЬНОЙ ВЕНОЗНОЙ ДИСФУНКЦИИ И РАЗНЫМ УРОВНЕМ АРТЕРИАЛЬНОГО ДАВЛЕНИЯ.....	107
Chorna V., Makhniuk V., Pshuk N., Gumeniuk N., Shevchuk Yu., Khliestova S. BURNOUT IN MENTAL HEALTH PROFESSIONALS AND THE MEASURES TO PREVENT IT	113
Ratiani L., Gegechkory S., Machavariani K., Shotadze T., Sanikidze T., Intskirveli N. THE PECULIARITY OF COVID-19 GENOME AND THE CORONAVIRUS RNA TRANSLATION PROCESS AS A POTENTIAL TARGET FOR ETIOTROPIC MEDICATIONS WITH ADENINE AND OTHER NUCLEOTIDE ANALOGUES (REVIEW).....	119
Patarashvili L., Azmaipharashvili E., Jandieri K., Gvidiani S., Tsomaia K., Kikalishvili L., Sareli M., Chanukvadze I., Kordzaia D. LIVER EXTRACELLULAR MATRIX PECULIARITIES IN MAMMALS AND AVIANS.....	124
Tsomaia K., Azmaipharashvili E., Gvidiani S., Bebiashvili I., Gusev S., Kordzaia D. STRUCTURAL CHANGES IN RATS' LIVER DURING THE FIRST 2 WEEKS FOLLOWING 2/3 PARTIAL HEPATECTOMY	134
Gvianishvili T., Kakauridze N., Gogiashvili L., Tsagareli Z., Kurtanidze T. CORRELATION OF THYROID AUTOIMMUNITY WITH ATHEROSCLEROSIS EVALUATION IN HASHIMOTO'S THYROIDITIS.....	142
Kiknadze T., Tevdorashvili G., Muzashvili T., Gachechiladze M., Burkadze G. PHENOTYPIC CHARACTERISTICS OF RELAPSED LEIOMYOMA AND SMOOTH MUSCLE TUMORS OF UNCERTAIN MALIGNANCY POTENTIAL IN REPRODUCTIVE WOMEN.....	150
Pkhakadze G., Bokhua Z., Asatiani T., Muzashvili T., Burkadze G. STEM CELL INDEX IN THE PROGRESSION OF CERVICAL INTRAEPITHELIAL NEOPLASIA.....	157
Pidlisetsky A., Savosko S., Dolhopolov O., Makarenko O. PERIPHERAL NERVE LESIONS AFTER A MECHANICALLY INDUCED LIMB ISCHEMIA.....	165
Kolisnyk I., Voloshin O., Savchenko I., Yanchevskiy O., Rashidi B. ENZYMATIC ACTIVITY IN MICROSOMES, LIPID PEROXIDATION OF MICE HEPATOCYTES UNDER THE SODIUM FLUORIDE.....	169
Smagulova A., Katokhin A., Mambetpayeva B., Kulmaganbetova N., Kiyan V. A MULTIPLEX PCR ASSAY FOR THE DIFFERENTIAL DETECTION OF OPISTHORCHIS FELINEUS AND METORCHIS BILIS	176
Rigvava S., Karumidze N., Kusradze I., Dvalidze T., Tatrishvili N., Goderdzishvili M. BIOLOGICAL CHARACTERIZATION OF BACTERIOPHAGES AGAINST STREPTOCOCCUS AGALACTIAE	182
Deshko L., Udovenko Zh., Bulycheva N., Galagan V., Bulychev A. PROVISION OF THE RIGHT TO NON-INTERFERENCE WITH PRIVACY DURING MUSTER PROCESS WITH THE PARTICIPATION OF DOCTOR (FORENSIC EXPERT)	186
Теремецкий В.И., Николаенко Т.Н., Дидковская Г.В., Гмырин А.А., Шаповал Т.Б. КОНТРОЛЬ И НАДЗОР КАК СРЕДСТВА ПРЕДУПРЕЖДЕНИЯ И ВЫЯВЛЕНИЯ ПРАВОНАРУШЕНИЙ В СФЕРЕ ЗДРАВООХРАНЕНИЯ.....	192

PERIPHERAL NERVE LESIONS AFTER A MECHANICALLY INDUCED LIMB ISCHEMIA

¹Pidlisetsky A., ²Savosko S., ³Dolhopolov O., ⁴Makarenko O.

¹Lviv Regional Hospital for War Veterans and Repressed named after Yu. Lyba; ²Bogomolets National Medical University, Department of Histology and Embryology; ³SI "Institute of Traumatology and Orthopedics under NAMS of Ukraine; ⁴Interregional Academy of Personnel Management, Ukraine

Non-compression damage to peripheral nerves of a limb is not a frequent trauma to extremities. Non-compression ischemia relates to lesions of a limb's great vessels (atherosclerosis, emboli, vasculitis, others). Frequently, they are consequences of a traumatic injury to an extremity [16]. A range of publications [17] contains selective descriptions of clinical cases of ischemic neuropathy, but the pathogenesis of damage to nerves of a limb remains understudied and unstructured. The reasons thereof are that the authors in their clinical researches describe separate cases with different etiology, while experimental studies made us able to investigate the development of damage to a limb's nerves and their recovery. Their main disadvantage was the focus on just a single factor as a task – ischemia of a nerve, while clinical cases are complicated with the probable presence of two – ischemia itself and pressure on the nerve. Moreover, the experimental researches mostly limit themselves by one or two models of isolated nerve compression [8, 10]. Although, such cases rarely occur in clinical practice, and the majority of the compression lesions are the consequences of a simultaneous trauma and compression to a limb with significant damage to skeletal muscles followed by their atrophy, tissue necrosis.

Acute necrosis of skeletal muscles and consequences thereof (myoglobinuria, impaired metabolism of electrolytes, acute renal impairment) are covered by scholars better, compared to the same of nerves of limbs. The conditions of peripheral nerves in compression and non-compression ischemia could reflect all the tissues of the extremity and the efficiency of the therapy in general. Besides, the literature sources lack enough data on the extent of the damage to muscles and peripheral nerves of an extremity in compression injury, and, which is the most important, their sensitivity to damage and stimulation of repairing processes.

In traumatology, the autologous tissue technologies are widely used, in particular for managing arthritis, traumas to a limb's nerves and tendons. Quite simple to obtain and use, and very promising are concentrates of platelet-rich plasma (PRP) and cells collected from the bone marrow aspirates (CBMA), and homogenized adipose tissue (HAT) derivable, especially in cases of peripheral neuropathies [10]. We found a range of researches with positive and promising results of the use thereof in the management of damages to the peripheral nervous system. The technology seems useful for the therapy of compression-ischemia neuropathies of the nerves in cases after a compartment syndrome.

Using experimental models of compression ischemia of a limb or peripheral nerves, we obtained a significant amount of data, but we should not equate all the results with the same of a human compression ischemia, so these disorders require further study.

The task of the research is to study damages to a sciatic nerve in mechanically-induced limb ischemia and after PRP, CBMA, and HAT injections.

Material and methods. *The background of the research is the animal model, a mechanically induced ischemia (MII).* The study involved Chinchilla rabbits (weighing 4.2-4.5 kg). The

rabbits lived in standard cages with free access to food and water. We subdivided the animals into five groups, five animals each: group 1 (control) – intact animals; group 2 (MII) – animals with an injured limb; group 3 (MII+PRP) – animals with an injured limb treated by PRP; group 4 (MII+CBMA) – animals with an injured limb treated by CBMA; group 4 (MII+HAT) – animals with an injured limb treated by HAT.

MII was simulated by an elastic medical tourniquet (5.5 cm wide, eight units per an extremity), lasting through the middle third of a left hind limb, from the thigh to the ankle joint. It thereby immobilized the limb and caused impaired vascular perfusion of the skeletal muscles of the tibia (SMT). We removed the tourniquets after 6 hours.

The subfascial pressure. For the subfascial pressure measuring, we applied a classical invasive method *Whitesides* in an anterolateral sleeve of a shin, using a standard device *Stryker Intra-Compartmental Pressure Monitor* (USA) for a one-shot measurement of every value [2].

The cells suspensions preparation. The cell suspensions were injected into the upper third of the SMT once, 6 hours after the elastic tourniquet removal. Test animals got withdrawn for the experiment in 5th, 15th, and 30th days after it started with the limb MII (5 animals for each stage thereof).

The animals received anesthesia with 60 mg/kg sodium thio-pental, intraperitoneal.

Platelet-rich plasma (PRP). We drew 5 ml of blood from the ear vein of a rabbit. By centrifuging the whole blood in an *Arthrex* tube (*Arthrex ACP® Double Syringe System*, *Arthrex, Inc. USA*) for 8 minutes at 760g, we obtained 1 ml of PRP under the layer of erythrocyte mass (the average platelet quantity was 928,000/ml).

Autologous concentrated bone marrow aspirate (CBMA). We aspirated 2 mL of bone marrow from the proximal part of an intact femur, with a 10G bone puncture needle and 5 mL syringe, like in the article [1]. To separate the aspirate, we used a Tulip Emulsifier filter (Tulip Medical Products, USA). After centrifuging of the aspirate with dextrose citrate coagulate – solution A (1:8) (*Baxter C.A., USA/Belgium*) for 8 minutes at 760g, we got 1.0 mL of supraerythrocytic fraction (the average cell quantity in native aspirate – 55.800/ml).

Homogenized adipose tissue (HAT). Through the access 2 cm, we took 5 mg of an abdominal gland and fined it as a suspension. For homogenization, the said suspension passed through a 1mm hole of two connected syringes.

Histological study. Sciatic nerves and SMTs of rabbits were fixed in 10% formalin solution in PBS (pH 7.4) for 24 hours at 4° C. The 15 µm slices of sciatic nerves, obtained with a cryotome, we impregnated with silver nitrate. On longitudinal sections of the nerve, we calculated the number of nerve fibers in the test area (the transverse axis of the nerve – 420 µm, in the micrograph – 420×550 µm; 0.23 mm²).

Electron microscopy. The samples of tibial nerve were fixed in 2.5% solution of glutaraldehyde in phosphate buffer with 1% osmium tetrachloride, dehydrated in increasing concentrations of ethanol and acetone. The tissue samples we embedded in

the Epone-Araldite mixture. To get the ultrathin slices, we applied an ultratome (*Reihart*). For contrast, we used 2% sodium citrate and uranyl acetate. To analyze the sections obtained, we scanned them with an electron microscope *Tescan Mira 3 LMU* (Czech Republic) (STEM detector).

Statistical analysis. The data obtained appeared as mean values (M) \pm standard errors of the means (SEM) and have been compared using Mann-Whitney U-test. We took the differences as significant at $P < 0.05$.

Bioethics. All manipulations with the animals complied with the European Convention for the protection of vertebrate animals used for experimental and other scientific purposes, # 123, Council of Europe, L222, 24/08/1999, p. 31 and the Commission on Bioethics of the State Institution “The Institute of Traumatology and Orthopedics under NAMS of Ukraine.”

Result and discussion. Macroscopic studies. After the MII, limb muscles were specific with acute edema and aggregation of intestinal tissue. After the incision of the fascia, we registered the emission of 0.5 to 2.0 ml of the liquid. Large and medium subfascial vessels on the knee level and shin muscles (*tibialis anterior*, *flexor digitorum longus*, *gastrocnemius*) were visually full with excessive blood, with the areas of hemorrhagic leakages in muscle sections. The texture of shin muscles changed: the surface muscles were edematous, soft, decolorized (from pink to yellowish-white). The deep muscles were more elastic and pink. On the 15th day, the extent of the edema was lower, compared to the 5th day, and the tissue of the muscles – more elastic, while in 30th days after the experiment started, there was no excessive interstitial fluid anymore. The color of the muscle tissues changed towards pinky-yellow, yellowish-white. The group of animals treated with PRP and CBMA had no injection areas; in the group of HAT, the areas of the insertion of the suspension were clear, specific with the excessive formation of connective tissues and angiogenesis, evidencing encapsulation of the aspirate. In all the animals with MII, we have detected the preservation of the integrity of sciatic nerves. The nerve was in the intramuscular space, without any signs of fibrosis processes along with it. The vessel network of the nerve and paraneural surroundings were distinct, the vessels full in blood, but without signs of hemorrhagic penetration into the intramuscular space. In other words, the mechanical damage to muscles of the shin, aggregation on interstitial fluid, and muscle tissue edema occur after the MII, decrease after the 5th day, and get replaced with necrotic changes in muscles without significant lesions to the sciatic nerve.

Microscopic changes in peripheral nerves of a limb. In longitudinal sections of nerves, we studied the structural changes of its fibers in the sciatic nerve fascicles. The nerve’s integrity was intact, the same for the fascicular structure. The sheaths of nerves had no reasonable damages, except for epineurium. We have noticed an increased density of fibroblasts, evidencing cellular reactions in the stromal elements of the nerve, cell proliferation in the epineurium. Nerve fibers were present in the nerve’s fascicles (Fig. 1), but their density had no significant differences within the period of the experiment (5, 15, and 30 days) and in terms of control. However, we have revealed deformed fibers with the different thickness of their myelin sheaths. On the 30th day after the MII, we identified “free” neurolemmocytes along the nerve fibers.

The distortion of a myelin sheath ultrastructure confirmed itself under electron microscopy (STEM). We studied the samples of the tibial nerve. On the 5th and 15th day, we noticed the im-

pairment in the density of myelin lamellae, myelin sheath deformities, and necrotized fibers (Fig. 2). In the impaired myelin fibers, the axial cylinders could be intact (with microtubules, mitochondria, vesicles) or exfoliated from the myelin. The cytoplasm of neurolemmocytes contained atypical lamellar (membrane) structures, the primary pathologic feature of autophagy. Despite degeneration ovoids, appearing after the total disintegration of a myelin fiber, the cytosolic lamellar inclusions result from autophagy, alternation of the damaged myelin in neurolemmocytes, and are the signs of dystrophy [14]. The PRP, CBMA, and HAT groups had no significant difference in the extent of the damage to the nerve. All the samples studied confirmed the demyelination and necrosis. The changes in the myelin fibers were not specific and frequently diffused. Consequently, we concluded no dependence on the level of the damage in the separate fascicles.

We have not confirmed severe nerve fibers degeneration in part of sciatic nerve, although disclosed the trend to the reduction in their density (Fig. 3). In PRP, CBMA, and HAT groups, we registered no “free” neurolemmocytes. This fact can be the evidence of less damage to the nerve fibers after the MII; there were no clear morphologic signs of the nerve fibers’ progressive degeneration in terms from 5th day to 30th day. It only means that the demyelination and degeneration of isolated nerve fibers occurs on the MII level and distally away from the compressive ischemia level, in particular in tibial nerve.

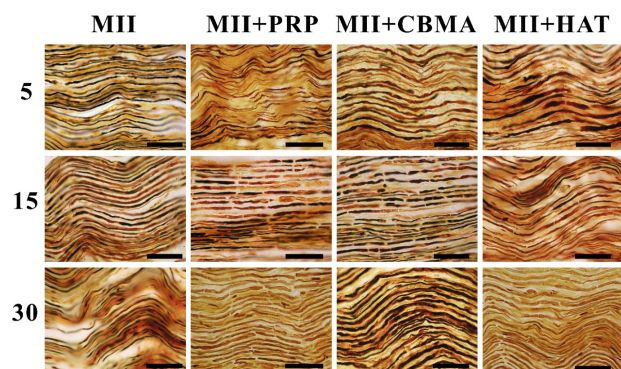


Fig. 1. A sciatic nerve of a rabbit on the 5th, 15th, and 30th day after the MII and the therapy. The impregnation with silver nitrate, scale bar 100 μ m

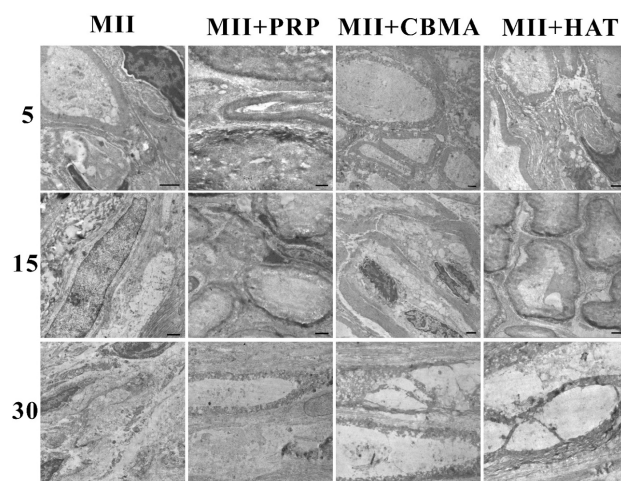


Fig. 2. A tibial nerve of a rabbit on the 5th, 15th, and 30th day after the MII and the therapy. Electron microscopy, scale bar 1 μ m

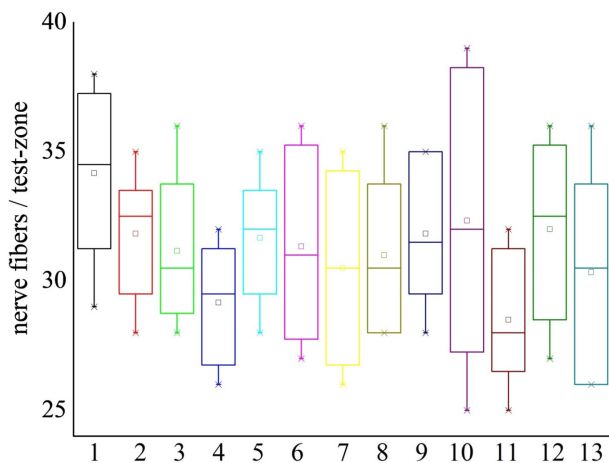


Fig. 3. The average amount of nerve fibers in the test-zones of a sciatic nerve after the MII and the injections of PRP, CBMA, and HAT

Note: 1 – control group; 2, 3, and 4 – MII on the 5th, 15th, and 30th day; 5, 6, and 7 – MII+PRP on the 5th, 15th, and 30th day; 8, 9, and 10 – MII+CBMA on the 5th, 15th and 30th day; 11, 12, and 13 – MII+HAT on the 5th, 15th, and 30th day

Analyzing the results of our own studies and the published articles, we concluded that muscles and peripheral nerves of a limb have different resistance against the compression ischemia. The skeletal muscles of a limb obviously endure significant damage from its compression. At the same time, the two factors, compression, and ischemia affect the limb's muscles and nerves, but it is not always possible to distinguish between the morphologic consequences of both ischemic injury and compression ischemia, as the expressions of the cellular necrosis are non-specific.

Descriptions of damage to muscles, their dystrophy, and slight signs of regeneration appear already in publications. In the focus of our interest, we have another aspect of compression of a limb, namely peripheral nerve conditions. We assumed that large nerves of extremities, like a sciatic one, could avoid suffering from the necrosis thanks to their specific anatomical position in the limb. Perhaps, their deep anatomical placement in an intramuscular space of a limb can prevent severe compressive damage. We also investigated how PRP, CBMA, and HAT therapy can influence these changes.

The analysis of clinical cases showed that the loss of nerve fibers in chronic non-compression ischemia is not critical; it may be less than 5% of myelin fibers. The basic expressions of the disorder are disproportionately thin myelin sheath, demyelination of the fibers, myelin fibers deformities [13]. The reduced speed of nerve impulses is thus predetermined by an axonal degeneration rather than by a demyelination process [6]. However, spontaneous recovery is also possible. Thus, Hitoshi Nukada et al. have described regenerating nerve fibers in the ischemically damaged nerves of a limb after 1-6 months [13]. Damage to nerves and further nerve fibers degeneration can occur without a significant muscle injury [18]. This fact could be explained by the higher vulnerability of nerve fibers to ischemia, compared to the muscle tissue [12]. Thus, in critical ischemia of a lower limb, Kudykin M.N. et al. reported muscle hypotrophy in 40% of cases, but neuropathy – in 100% [7].

In an experimental paper, a ligature to an aorta does not cause total muscle ischemia due to the collateral blood flow; muscles and nerves suffer equally upon such conditions [3]. According to other data, in non-compression ischemic neuropathies, degenerative muscle changes could progress without significant necrosis of

muscles, confirming the hypothesis that human distal nerve fibers, compared to muscle tissues, are more vulnerable to the acute non-compression ischemia of limbs [18]. After the limited microemboli of limb arteries, was reported the necrosis of small groups of muscle fibers, but muscles regenerate further [4]. In such cases, regeneration launches one month after the injury, while muscle fibrosis does not develop in non-compression ischemia.

Having analyzed the literature, we assumed that the extent of the nerve lesion depends directly on the value of compression of a limb by a tourniquet applied to the extremity. We came to this conclusion on the background of the absence of acute necrosis to structural elements of the sciatic nerve after 6 hours of the limb's compression, while degeneration, destruction of nerve fibers' myelin expressed brightly on the level of the tibial nerve, topographically equal to and distally from the compression area. The data described vary in different authors; this relates to the various methods used for study, like only electrophysiological or morphological. Thus, if the compression ischemia lasts more than 2 hours, the extent of degeneration progresses [3], while in other cases described, 12-hours compressing ischemia leads only to endoneurial edema [9]. Compression with a tourniquet on the level of 250 mm Hg leads only to a reversible nerve blockade, at 500 mm Hg – rarely to demyelination, while at 1000 mm Hg – to demyelination and mechanical damage to the nerve [3]. In the research, we determined the subfascial pressure, 30-70 mm Hg at the 3rd-6th hour of the MII. The discovered difference in the damage to the sciatic and tibial nerves indicates the difference in subfascial and intra-tissue pressures, reflected in more significant damage to a tibial nerve, due to its anatomic peculiarities placed more superficially, compared to the sciatic one.

During the first 4-6 hours after the tourniquet removal, the nerve conduction remained, while 8 hours later is did not restored [9]. Hence, on the background of these periods, one can say about a "therapeutic window" in compressive ischemia management. During the same time, we inserted PRP, CBMA, and HAT into the skeletal muscles of the shin. Histological and morphometrical studies showed neither positive nor negative results of the insertion of tissue suspension into the damaged muscles.

In all the samples of the nerves, we saw different types of damages: unequal thickness and myelin deformities, atypically thin fibers, degeneration of the axial cylinders, lamellar structures in neurolemmocytes, partial destruction of a nerve's endoneurium. These changes were not all out; we have observed just a tendency to the decreased density of nerve fibers in the sciatic nerve on the 30th day after the MII, although the dystrophy of nerve fibers has already been noticed distally, in the tibial nerve. In other research, Richards R.L. described a significant increase in endoneurial collagen, progressing till complete replacement of the nerve bundles with collagen [5]. However, we have not discovered fibrosis in our own studies (except for the destruction of endoneurium and perineurium, isolated cell-less areas rich in collagen). We assessed all revealed disorders as the consequences of damage to the limb's blood vessels, because the injuries to vessels (stasis, thrombosis, lytic cell death in vessels) occurred as in muscles' myons, as in the capillaries of intramuscular space (unpublished data). However, the changes did not reach the total degeneration of the nerve. This fact could have several explanations. The blood supply to a limb's peripheral nerve is multilevel, and the vessels cover reasonably the areas on different levels. Damage to a nerve due to a focal loss of perfusion has been considered before as highly improbable because collateral vessels ensure proper blood circulation in the nerve [5]. At the same time, the difference between vascularization and revascu-

larization of a limb muscles exist. Thus, “fast muscles” (*soleus*) have a higher density of micro-vessels, more of them per muscle fiber, are longer, and with better VEGF expression, compared to the “slow muscles” (*extensor digitorum longus*). The explanation is in diverse physiology of various types of fibers in these muscles, their need for different oxygenation of the “fast” and “slow” aerobic and “fast” anaerobic fibers [15]. In our experiment, we neglected this division, as the compression ischemia was significant, non-selective, and led to the total necrosis of peripheral myons in all the muscles of a shin.

Consequently, the compression ischemia of a limb causes mild or moderate damage to the peripheral nerves of a limb, depending on the level of compression. Inserting PRP, CBMA, and HAT into the ischemic limb muscles showed no reliable effect on the development of structural changes in peripheral nerves while studying these processes in the ischemically damaged muscle fibers seems promising.

REFERENCES

1. Gaiovych I., Savosko S., Labunets I., Utko N., Makarenko A., Chaikovskiy Y. Sciatic nerve regeneration after autografting and application of the bone marrow aspirate concentration.// Georgian Med News, 2019, 295, 145-152.
2. Halanski M.A., Morris M.R., Lee Harper B., Doro C. Intracompartmental Pressure Monitoring Using a Handheld Pressure Monitoring System.// JBJS essential surgical techniques, 2015, 5(1).
3. Harriman D.G. Ischaemia of peripheral nerve and muscle.// J ClinPatholSuppl (R CollPathol), 1977, 11, 94-104.
4. Hathaway P.W., Engel W.K., Zellweger H. Experimental myopathy after microarterial embolization: Comparison with childhood X-linked pseudohypertrophic muscular dystrophy.// Archives of Neurology, 1970, 22, 365-378.
5. Richards R.L. Ischaemic lesions of peripheral nerves: a review.// J Neurol Neurosurg Psychiatry, 1951, 14(2), 76-87.
6. Kaku D.A., Malamut R.I., Frey D.J., Parry G.J. Conduction block as a nearly sign of reversible injury in ischemic monomelic neuropathy.// Neurology, 1993, 43(6), 1126-1130.
7. Kudykin M.N., Sheiko G.E., Belova A.N. Peripheral neuropathy in critical limb ischemia.//RMJ, 2018, 6(II), 70-73.
8. Liu Z.Y., Chen Z.B., Chen J.H. A novel chronic nerve compression model in the rat.// Neural Regen Res, 2018, 13(8), 1477-1485.
9. Lundborg G. Limb ischemia and nerve injury.//ArchSurg, 1972, 104(5), 631-632.
10. Malahias M.A., Chytas D., Babis G.C., Nikolaou V.S. Platelet-rich plasma guided injections: clinical application in peripheral neuropathies.//FrontSurg. 2014, 1, 41.
11. Muthuraman A., Ramesh M., Sood S. Development of animal model for vasculitic neuropathy: Induction by ischemic-reperfusion in the rat femoral artery.// Journal of Neuroscience Methods, 2010, 186(2), 215-221.
12. Nukada H. Ischemic neuropathy.// Rinsho Shinkeigaku, 1990, 30(12), 1368-1370.
13. Nukada H., van Rij A.M., Packer S.G.K., McMoran P.D. Pathology of acute and chronic ischaemic neuropathy in atherosclerotic peripheral vascular disease.//Brain, 1996, 119(5), 1449-1450.
14. Park H.T., Kim J.K., Tricaud N. The conceptual introduction of the “demyelinating Schwann cell” in peripheral demyelinating neuropathies.//Glia, 2019, 67(4), 571-581.
15. Ranjbar K., Fayazi B. Vascularisation of Skeletal Muscle. In: Muscle Cells - Recent Advances and Future Perspectives. Ed. by Mani T. Valarmathi. Intech Open, 2019, 180.
16. Sorokin Yu.N., Sagaradze S.A., Melnikov A.V. Acute Ischemic Neuropathy.//International Neurological Journal [S.I.], 2014, 2(64), 100-105.
17. Ugalde V., Rosen BS. Ischemic peripheral neuropathy.//Phys Med RehabilClin N Am, 2001, 12(2), 365-380.
18. Wilbourn A.J., Furlan A.J., Hulley W., Ruschhaupt W. Ischemic monomelic neuropathy.//Neurology, 1983, 33(4), 447-451.

SUMMARY

PERIPHERAL NERVE LESIONS AFTER A MECHANICALLY INDUCED LIMB ISCHEMIA

¹Pidlissetskyy A., ²Savosko S., ³Dolhopolov O., ⁴Makarenko O.

¹Lviv Regional Hospital for War Veterans and Repressed named after Yu. Lypa; ²Bogomolets National Medical University, Department of Histology and Embryology; ³SI “Institute of Traumatology and Orthopedics under NAMS of Ukraine; ⁴Interregional Academy of Personnel Management, Ukraine

The article describes the results of studying the changes in peripheral nerves of a limb after a mechanically induced ischemia. It assessed myelinated nerve fibers in sciatic and tibial nerves after 6 hours of ischemia, simulated by a tourniquet on the level of a tibial, knee, and a lower third of a femur. Fasciculi of the sciatic nerve have shown no changes in the density of nerve fibers in 5th, 15th, and 30th days after the simulated ischemia, but we revealed the deformed fibers with the different thickness of myelin sheath. In a tibial nerve, myelin loss and deformations occurred on the 5th and 15th day, and atrophy of nerve fibers – on the 15th and 30th days. Neurolemmocytes of the injured myelin nerve fibers demonstrate the signs of dystrophic processes and autophagy. After the insertion of platelet-rich plasma, concentrated bone marrow aspirate, and homogenized adipose tissue in the ischemically damaged muscles, not a significant difference appeared between the extent of damage to the nerve. Consequently, the structural signs of the damage to peripheral nerves depend more on the level of injury to a limb than on therapy with autologous cellular technologies.

Keywords: ischemia of limb, peripheral nerve, morphometry, platelet-rich plasma, concentrated bone marrow aspirate, homogenized adipose tissue.

РЕЗЮМЕ

ПОВРЕЖДЕНИЯ ПЕРИФЕРИЧЕСКИХ НЕРВОВ КОНЕЧНОСТИ ПРИ МЕХАНИЧЕСКИ-ИНДУЦИРОВАННОЙ ИШЕМИИ

¹Пидлисецкий А.Т., ²Савосько С.И., ³Долгополов А.В., ⁴Макаренко А.Н.

¹Львовский областной госпиталь ветеранов войн и репрессированных им. Ю. Липы; ²Национальный медицинский университет им. А.А. Богомольца, кафедра гистологии и эмбриологии, Киев; ³ГУ «Институт ортопедии и травматологии НАМН Украины», Киев; ⁴Межрегиональная Академия управления персоналом, Киев, Украина

В статье описаны результаты исследования изменений периферических нервов конечности после механически индуцированной ишемии. Оценены миелиновые нервные волокна в седалищном и большеберцовом нервах после 6-ча-

своей ишемии, моделированной жгутом на уровне голени, коленного сустава и нижней трети бедра. В фасцикулах седального нерва изменений плотности нервных волокон на 5, 15 и 30 сутки после моделирования ишемии не выявлено, однако обнаружены деформированные волокна с разной толщиной миелиновой оболочки. В большеберцовом нерве на 5 и 15 сутки установлены демиелинизация и деформация миелина, а на 15 и 30 сутки – атрофия нервных волокон. В нейролемоцитах поврежденных миелиновых нервных волокон выявлены признаки дистрофических процессов и

аутофагии. После введения в ишемически поврежденные мышцы тромбоцитарной плазмы, концентрата клеток аспирата костного мозга и гомогенизированной жировой ткани существенной разницы в степени повреждения нерва не выявлено. Сделано заключение, что структурные признаки повреждения периферических нервов конечности после ишемии являются неспецифическими и в большинстве случаев зависят от уровня повреждения конечности, чем от терапевтических подходов с использованием аутологических клеточных технологий.

რეზიუმე

კიდურის პერიფერიული ნერვების დაზიანებანი მექანიკურად ინდუცირებული იშემიის დროს

¹ა.პიდლისეცკი, ²ხ.სავოსკო, ³ა.დოლგოპოლოვი, ⁴ა.მაკარენკო

¹ღვოვის იუ.ლიპის სახ. ომის ვეტერანებისა და რეპრესირებულების საოლქო ჰოსპიტალი;

²ა.ბოგომლეცის სახ. ეროვნული სამედიცინო უნივერსიტეტი, ჰისტოლოგიისა და ემბრიოლოგიის კათედრა;

³უკრაინის მედიცინის მეცნიერებათა აკადემიის ორთოპედისა და ტრავმატოლოგიის ინსტიტუტი, კიევი;

⁴პერსონალის მართვის რეგიონთაშორისი აკადემია, კიევი, უკრაინა

სტატიაში წარმოდგენილია კიდურის პერიფერიული ნერვების ცვლილებების კვლევის შედეგები მექანიკურად ინდუცირებული იშემიის შემდეგ. შეფასებულია მიელინის ნერვული ბოჭკოები საჯდომ და დიდი წვივის ნერვებში 6-საათიანი იშემიის შემდეგ, რაც მოდელირებული იყო ლახტის გადაჭერით წვივის, მუხლის სახსრის და ბარძაყის ქვედა მესამედის დონეზე. საჯდომი ნერვის ფასციკულაში ნერვული ბოჭკოების სიმჭიდროვის ცვლილებები იშემიის მოდელირებიდან მე-5, მე-15 და 30-ე დღეს არ გამოვლინდა, თუმცა, აღმოჩენილია დეფორმირებული ბოჭკოები მიელინის გარის სხვადასხვა სისქით. დიდი წვივის ნერვში მე-5 და მე-15 დღეს დადგენილია დემიელინიზაცია და მიელინის დეფორმაცია, ხოლო მე-15 და 30-ე დღეს – ნერვული

ბოჭკოების ატროფია. დაზიანებული მიელინის ნერვული ბოჭკოების ნეიროლემოციტებში გამოვლინდა დისტროფიული პროცესების და აუტოფაგიის ნიშნები. იშემიურად დაზიანებულ კუნთებში თრომბოციტული პლაზმის, ძვლის ტენის ასპირატის უჯრედების კონცენტრატის და ჰომოგენიზებული ცხიმოვანი ქსოვილის შეყვანის შემდეგ არსებითი განსხვავება ნერვის დაზიანების ხარისხში არ აღინიშნა. ავტორები დაასკვნან, რომ კიდურის პერიფერიული ნერვების დაზიანებების ნიშნები იშემიის შემდეგ არასპეციფიკურია და, უმეტეს შემთხვევაში, მეტადაა დამოკიდებული კიდურის დაზიანების ხარისხზე, ვიდრე თერაპიულ მიდგომებზე აუტოლოგიური უჯრედული ტექნოლოგიების გამოყენებით.

ENZYMATIC ACTIVITY IN MICROSOMES, LIPID PEROXIDATION OF MICE HEPATOCYTES UNDER THE SODIUM FLUORIDE

¹Kolisnyk I., ²Voloshin O., ²Savchenko I., ²Yanchevskiy O., ²Rashidi B.

¹Kharkiv Medical Academy of Postgraduate Education;

²The State Institution "Lugansk State Medical University", Rubizhne, Ukraine

Fluorine is one of the most widespread and necessary microelements for the body of animals and humans, which is required in a clearly limited amount [9,10]. The biological role of this microelement is difficult to overestimate, since it is part of the tooth enamel, bones, participates in the formation of dentin, and also prevents the development of osteoporosis with age. For many biological processes, it serves as a catalyst or inhibitor [7,11,15].

Different concentrations of fluorine can affect the state of lipid peroxidation, as well as the functional state of the microsomes of liver hepatocytes. With prolonged ingestion, fluoride can lead to fluorosis [6,10,13,14].

The question of the physiological role of fluorine on the body remains open, since an excess of this trace element in the composition of water is the cause of the destruction of tooth enamel, inhibition of phosphorus-calcium and carbohydrate metabolism, and the

activity of a number of enzymes. Due to this, fluorine can lead to the suppression of some intracellular processes in the body, reduce the activity of the immune system [5]. Acute fluoride intoxication leads to a decrease in the intensity of tissue respiration, the formation of reactive oxygen species by cells increases, lipid peroxidation processes increase, and the activity of antioxidant defense enzymes decreases. With the alimentary pathway of sodium fluoride entering the body, its negative effect affects the structure and function of the digestive system, primarily the liver [1].

It was found that the effect of sodium fluoride leads to an increase in all parameters of microsomal oxidation of hepatocytes, with the exception of cytochrome b5 [2-5,8]. This circumstance allows us to put forward the idea of stimulating free radical processes leading to disruption in the structure of hepatocyte membranes, oxidative destruction of biologically active substances [4].