

# GEORGIAN MEDICAL NEWS

ISSN 1512-0112

NO 9 (354) Декабрь 2024

ТБИЛИСИ - NEW YORK



ЕЖЕМЕСЯЧНЫЙ НАУЧНЫЙ ЖУРНАЛ

Медицинские новости Грузии  
საქართველოს სამედიცინო სიახლენი

## GEORGIAN MEDICAL NEWS

Monthly Georgia-US joint scientific journal published both in electronic and paper formats of the Agency of Medical Information of the Georgian Association of Business Press.  
Published since 1994. Distributed in NIS, EU and USA.

**GMN: Georgian Medical News** is peer-reviewed, published monthly journal committed to promoting the science and art of medicine and the betterment of public health, published by the GMN Editorial Board since 1994. GMN carries original scientific articles on medicine, biology and pharmacy, which are of experimental, theoretical and practical character; publishes original research, reviews, commentaries, editorials, essays, medical news, and correspondence in English and Russian.

GMN is indexed in MEDLINE, SCOPUS, PubMed and VINITI Russian Academy of Sciences. The full text content is available through EBSCO databases.

**GMN: Медицинские новости Грузии** - ежемесячный рецензируемый научный журнал, издаётся Редакционной коллегией с 1994 года на русском и английском языках в целях поддержки медицинской науки и улучшения здравоохранения. В журнале публикуются оригинальные научные статьи в области медицины, биологии и фармации, статьи обзорного характера, научные сообщения, новости медицины и здравоохранения. Журнал индексируется в MEDLINE, отражён в базе данных SCOPUS, PubMed и ВИНТИ РАН. Полнотекстовые статьи журнала доступны через БД EBSCO.

**GMN: Georgian Medical News** – საქართველოს სამედიცინო სიახლენი – არის ყოველთვიური სამეცნიერო სამედიცინო რეცენზირებადი ჟურნალი, გამოიცემა 1994 წლიდან, წარმოადგენს სარედაქციო კოლეგიისა და აშშ-ის მეცნიერების, განათლების, ინდუსტრიის, ხელოვნებისა და ბუნებისმეტყველების საერთაშორისო აკადემიის ერთობლივ გამოცემას. GMN-ში რუსულ და ინგლისურ ენებზე ქვეყნდება ექსპერიმენტული, თეორიული და პრაქტიკული ხასიათის ორიგინალური სამეცნიერო სტატიები მედიცინის, ბიოლოგიისა და ფარმაციის სფეროში, მიმოხილვითი ხასიათის სტატიები.

ჟურნალი ინდექსირებულია MEDLINE-ის საერთაშორისო სისტემაში, ასახულია SCOPUS-ის, PubMed-ის და ВИНТИ РАН-ის მონაცემთა ბაზებში. სტატიების სრული ტექსტი ხელმისაწვდომია EBSCO-ს მონაცემთა ბაზებიდან.

### WEBSITE

[www.geomednews.com](http://www.geomednews.com)

## К СВЕДЕНИЮ АВТОРОВ!

При направлении статьи в редакцию необходимо соблюдать следующие правила:

1. Статья должна быть представлена в двух экземплярах, на русском или английском языках, напечатанная через **полтора интервала на одной стороне стандартного листа с шириной левого поля в три сантиметра**. Используемый компьютерный шрифт для текста на русском и английском языках - **Times New Roman (Кириллица)**, для текста на грузинском языке следует использовать **AcadNusx**. Размер шрифта - **12**. К рукописи, напечатанной на компьютере, должен быть приложен CD со статьей.

2. Размер статьи должен быть не менее десяти и не более двадцати страниц машинописи, включая указатель литературы и резюме на английском, русском и грузинском языках.

3. В статье должны быть освещены актуальность данного материала, методы и результаты исследования и их обсуждение.

При представлении в печать научных экспериментальных работ авторы должны указывать вид и количество экспериментальных животных, применявшиеся методы обезболивания и усыпления (в ходе острых опытов).

4. К статье должны быть приложены краткое (на полстраницы) резюме на английском, русском и грузинском языках (включающее следующие разделы: цель исследования, материал и методы, результаты и заключение) и список ключевых слов (key words).

5. Таблицы необходимо представлять в печатной форме. Фотокопии не принимаются. **Все цифровые, итоговые и процентные данные в таблицах должны соответствовать таковым в тексте статьи**. Таблицы и графики должны быть озаглавлены.

6. Фотографии должны быть контрастными, фотокопии с рентгенограмм - в позитивном изображении. Рисунки, чертежи и диаграммы следует озаглавить, пронумеровать и вставить в соответствующее место текста **в tiff формате**.

В подписях к микрофотографиям следует указывать степень увеличения через окуляр или объектив и метод окраски или импрегнации срезов.

7. Фамилии отечественных авторов приводятся в оригинальной транскрипции.

8. При оформлении и направлении статей в журнал МНГ просим авторов соблюдать правила, изложенные в «Единых требованиях к рукописям, представляемым в биомедицинские журналы», принятых Международным комитетом редакторов медицинских журналов - <http://www.spinesurgery.ru/files/publish.pdf> и [http://www.nlm.nih.gov/bsd/uniform\\_requirements.html](http://www.nlm.nih.gov/bsd/uniform_requirements.html) В конце каждой оригинальной статьи приводится библиографический список. В список литературы включаются все материалы, на которые имеются ссылки в тексте. Список составляется в алфавитном порядке и нумеруется. Литературный источник приводится на языке оригинала. В списке литературы сначала приводятся работы, написанные знаками грузинского алфавита, затем кириллицей и латиницей. Ссылки на цитируемые работы в тексте статьи даются в квадратных скобках в виде номера, соответствующего номеру данной работы в списке литературы. Большинство цитированных источников должны быть за последние 5-7 лет.

9. Для получения права на публикацию статья должна иметь от руководителя работы или учреждения визу и сопроводительное отношение, написанные или напечатанные на бланке и заверенные подписью и печатью.

10. В конце статьи должны быть подписи всех авторов, полностью приведены их фамилии, имена и отчества, указаны служебный и домашний номера телефонов и адреса или иные координаты. Количество авторов (соавторов) не должно превышать пяти человек.

11. Редакция оставляет за собой право сокращать и исправлять статьи. Корректур авторам не высылаются, вся работа и сверка проводится по авторскому оригиналу.

12. Недопустимо направление в редакцию работ, представленных к печати в иных издательствах или опубликованных в других изданиях.

**При нарушении указанных правил статьи не рассматриваются.**

## REQUIREMENTS

Please note, materials submitted to the Editorial Office Staff are supposed to meet the following requirements:

1. Articles must be provided with a double copy, in English or Russian languages and typed or computer-printed on a single side of standard typing paper, with the left margin of 3 centimeters width, and 1.5 spacing between the lines, typeface - **Times New Roman (Cyrillic)**, print size - 12 (referring to Georgian and Russian materials). With computer-printed texts please enclose a CD carrying the same file titled with Latin symbols.

2. Size of the article, including index and resume in English, Russian and Georgian languages must be at least 10 pages and not exceed the limit of 20 pages of typed or computer-printed text.

3. Submitted material must include a coverage of a topical subject, research methods, results, and review.

Authors of the scientific-research works must indicate the number of experimental biological species drawn in, list the employed methods of anesthetization and soporific means used during acute tests.

4. Articles must have a short (half page) abstract in English, Russian and Georgian (including the following sections: aim of study, material and methods, results and conclusions) and a list of key words.

5. Tables must be presented in an original typed or computer-printed form, instead of a photocopied version. **Numbers, totals, percentile data on the tables must coincide with those in the texts of the articles.** Tables and graphs must be headed.

6. Photographs are required to be contrasted and must be submitted with doubles. Please number each photograph with a pencil on its back, indicate author's name, title of the article (short version), and mark out its top and bottom parts. Drawings must be accurate, drafts and diagrams drawn in Indian ink (or black ink). Photocopies of the X-ray photographs must be presented in a positive image in **tiff format**.

Accurately numbered subtitles for each illustration must be listed on a separate sheet of paper. In the subtitles for the microphotographs please indicate the ocular and objective lens magnification power, method of coloring or impregnation of the microscopic sections (preparations).

7. Please indicate last names, first and middle initials of the native authors, present names and initials of the foreign authors in the transcription of the original language, enclose in parenthesis corresponding number under which the author is listed in the reference materials.

8. Please follow guidance offered to authors by The International Committee of Medical Journal Editors guidance in its Uniform Requirements for Manuscripts Submitted to Biomedical Journals publication available online at: [http://www.nlm.nih.gov/bsd/uniform\\_requirements.html](http://www.nlm.nih.gov/bsd/uniform_requirements.html)  
[http://www.icmje.org/urm\\_full.pdf](http://www.icmje.org/urm_full.pdf)

In GMN style for each work cited in the text, a bibliographic reference is given, and this is located at the end of the article under the title "References". All references cited in the text must be listed. The list of references should be arranged alphabetically and then numbered. References are numbered in the text [numbers in square brackets] and in the reference list and numbers are repeated throughout the text as needed. The bibliographic description is given in the language of publication (citations in Georgian script are followed by Cyrillic and Latin).

9. To obtain the rights of publication articles must be accompanied by a visa from the project instructor or the establishment, where the work has been performed, and a reference letter, both written or typed on a special signed form, certified by a stamp or a seal.

10. Articles must be signed by all of the authors at the end, and they must be provided with a list of full names, office and home phone numbers and addresses or other non-office locations where the authors could be reached. The number of the authors (co-authors) must not exceed the limit of 5 people.

11. Editorial Staff reserves the rights to cut down in size and correct the articles. Proof-sheets are not sent out to the authors. The entire editorial and collation work is performed according to the author's original text.

12. Sending in the works that have already been assigned to the press by other Editorial Staffs or have been printed by other publishers is not permissible.

**Articles that Fail to Meet the Aforementioned  
Requirements are not Assigned to be Reviewed.**

## ავტორთა საქურაღებოლ!

რედაქციაში სტატიის წარმოდგენისას საჭიროა დაიცვათ შემდეგი წესები:

1. სტატია უნდა წარმოადგინოთ 2 ცალად, რუსულ ან ინგლისურ ენებზე დაბეჭდილი სტანდარტული ფურცლის 1 გვერდზე, 3 სმ სიგანის მარცხენა ველისა და სტრიქონებს შორის 1,5 ინტერვალის დაცვით. გამოყენებული კომპიუტერული შრიფტი რუსულ და ინგლისურენოვან ტექსტებში - **Times New Roman (Кириллица)**, ხოლო ქართულენოვან ტექსტში საჭიროა გამოვიყენოთ **AcadNusx**. შრიფტის ზომა – 12. სტატიას თან უნდა ახლდეს CD სტატიით.

2. სტატიის მოცულობა არ უნდა შეადგენდეს 10 გვერდზე ნაკლებს და 20 გვერდზე მეტს ლიტერატურის სიის და რეზიუმეების (ინგლისურ, რუსულ და ქართულ ენებზე) ჩათვლით.

3. სტატიაში საჭიროა გაშუქდეს: საკითხის აქტუალობა; კვლევის მიზანი; საკვლევი მასალა და გამოყენებული მეთოდები; მიღებული შედეგები და მათი განსჯა. ექსპერიმენტული ხასიათის სტატიების წარმოდგენისას ავტორებმა უნდა მიუთითონ საექსპერიმენტო ცხოველების სახეობა და რაოდენობა; გაუტკივარებისა და დაძინების მეთოდები (მწვავე ცდების პირობებში).

4. სტატიას თან უნდა ახლდეს რეზიუმე ინგლისურ, რუსულ და ქართულ ენებზე არანაკლებ ნახევარი გვერდის მოცულობისა (სათაურის, ავტორების, დაწესებულების მითითებით და უნდა შეიცავდეს შემდეგ განყოფილებებს: მიზანი, მასალა და მეთოდები, შედეგები და დასკვნები; ტექსტუალური ნაწილი არ უნდა იყოს 15 სტრიქონზე ნაკლები) და საკვანძო სიტყვების ჩამონათვალი (key words).

5. ცხრილები საჭიროა წარმოადგინოთ ნაბეჭდი სახით. ყველა ციფრული, შემაჯამებელი და პროცენტული მონაცემები უნდა შეესაბამებოდეს ტექსტში მოყვანილს.

6. ფოტოსურათები უნდა იყოს კონტრასტული; სურათები, ნახაზები, დიაგრამები - დასათაურებული, დანომრილი და სათანადო ადგილას ჩასმული. რენტგენოგრამების ფოტოასლები წარმოადგინეთ პოზიტიური გამოსახულებით **tiff** ფორმატში. მიკროფოტოსურათების წარწერებში საჭიროა მიუთითოთ ოკულარის ან ობიექტივის საშუალებით გადიდების ხარისხი, ანათალების შედეგის ან იმპრეგნაციის მეთოდი და აღნიშნოთ სურათის ზედა და ქვედა ნაწილები.

7. სამამულო ავტორების გვარები სტატიაში აღინიშნება ინიციალების თანდართვით, უცხოურისა – უცხოური ტრანსკრიპციით.

8. სტატიას თან უნდა ახლდეს ავტორის მიერ გამოყენებული სამამულო და უცხოური შრომების ბიბლიოგრაფიული სია (ბოლო 5-8 წლის სიღრმით). ანბანური წყობით წარმოდგენილ ბიბლიოგრაფიულ სიაში მიუთითეთ ჯერ სამამულო, შემდეგ უცხოელი ავტორები (გვარი, ინიციალები, სტატიის სათაური, ჟურნალის დასახელება, გამოცემის ადგილი, წელი, ჟურნალის №, პირველი და ბოლო გვერდები). მონოგრაფიის შემთხვევაში მიუთითეთ გამოცემის წელი, ადგილი და გვერდების საერთო რაოდენობა. ტექსტში კვადრატულ ფხიხლებში უნდა მიუთითოთ ავტორის შესაბამისი N ლიტერატურის სიის მიხედვით. მიზანშეწონილია, რომ ციტირებული წყაროების უმეტესი ნაწილი იყოს 5-6 წლის სიღრმის.

9. სტატიას თან უნდა ახლდეს: ა) დაწესებულების ან სამეცნიერო ხელმძღვანელის წარდგინება, დამოწმებული ხელმოწერითა და ბეჭდით; ბ) დარგის სპეციალისტის დამოწმებული რეცენზია, რომელშიც მითითებული იქნება საკითხის აქტუალობა, მასალის საკმაობა, მეთოდის სანდოობა, შედეგების სამეცნიერო-პრაქტიკული მნიშვნელობა.

10. სტატიის ბოლოს საჭიროა ყველა ავტორის ხელმოწერა, რომელთა რაოდენობა არ უნდა აღემატებოდეს 5-ს.

11. რედაქცია იტოვებს უფლებას შეასწოროს სტატია. ტექსტზე მუშაობა და შეჯერება ხდება საავტორო ორიგინალის მიხედვით.

12. დაუშვებელია რედაქციაში ისეთი სტატიის წარდგენა, რომელიც დასაბეჭდად წარდგენილი იყო სხვა რედაქციაში ან გამოქვეყნებული იყო სხვა გამოცემებში.

აღნიშნული წესების დარღვევის შემთხვევაში სტატიები არ განიხილება.

Teona Avaliani, Nino Kiria, Nino Bablishvili, Giorgi Pichkhaia, Lali Sharvadze, Nana Kiria. USAGE OF SILVER NANOPARTICLES TO RESTORE MOXIFLOXACIN EFFICACY FOR FLUOROQUINOLONE-RESISTANT M.TUBERCULOSIS CULTURES.....	6-12
Kien Tran, Hung Kieu Dinh, Ha Duong Dai, Tan Hoang Minh, Van Hoang thi Hong, Trang Nguyen Thi Huyen, Mai Bui Thi. EFFECTIVENESS IN INDIRECT DECOMPRESSION USING MINIMALLY INVASIVE SURGERY – TRANSFORAMINAL LUMBAR INTERBODY FUSION IN SINGLE-LEVEL LUMBOSACRAL SPONDYLOLISTHESIS.....	13-18
Yuriy Prudnikov, Olha Yuryk, Mykhailo Sosnov, Anatoliy Stashkevych, Stepan Martsyniak. USE OF ARTIFICIAL INTELLIGENCE IN THE DIAGNOSIS AND TREATMENT OF ORTHOPEDIC DISEASES: LITERATURE REVIEW.....	19-31
Blerita Latifi-Xhemajli. EFFECTIVENESS OF XYLITOL TOOTHPASTE IN CARIES PREVENTION: A REVIEW ARTICLE.....	32-35
Bukia Nato, Machavariani Lamara, Butskhrikidze Marina, Svanidze Militsa, Siradze Mariam. ELECTROMAGNETIC STIMULATION REGULATES BLOOD CORTICOSTERONE LEVELS IN IMMOBILIZED RATS: GENDER DIFFERENCES.....	36-41
Arnab Sain, Urvashi Ghosh, Jack Song Chia, Minaal Ahmed Malik, Nauman Manzoor, Michele Halasa, Fahad Hussain, Hamdoon Asim, Kanishka Wattage, Hoosai Manyar, Ahmed Elkilany, Anushka Jindal, Justin Wilson, Nadine Khayyat, Hannah Burton, Wilam Ivanga Alfred, Vivek Deshmukh, Zain Sohail, Nirav Shah. RECENT TRENDS IN THE USE OF CELL SALVAGER FOR ORTHOPAEDIC TRAUMA AND ELECTIVE SURGERIES-A NARRATIVE REVIEW.....	42-44
Yu.V. Boldyreva, D.G. Gubin, I.A. Lebedev, E.V. Zakharchuk, I.V. Pashkina. ANALYSIS OF BLOOD PARAMETERS IN TYUMEN RESIDENTS WITH COVID-19 IN CATAMNESIS AND/OR VACCINATED AGAINST A NEW CORONAVIRUS INFECTION.....	45-48
Abuova Zh.Zh, Buleshov M.A, Zhaksybergenov A.M, Assilbekova G, Mailykaraeva A.A. THE STUDY OUTCOMES OF THE NEGATIVE IMPACT OF HEXACHLOROCYCLOHEXANE ON VEGETOVASCULAR REGULATION OF NEWBORNS' CARDIAC RHYTHM.....	49-56
Rostomov Faizo E, Sashkova Angelina E, Kruglikov Nikita S, Postnova Elina V, Nasirov Said F.O, Barinova Olga V, Repina Anastasiia F, Kozokova Farida A, Abdulmanatov Magomedemin K, Dzhamalova Asiiat M. THE ROLE OF PSYCHOLOGICAL STRESS IN THE DEVELOPMENT OF ESSENTIAL ARTERIAL HYPERTENSION IN ELDERLY PEOPLE.....	57-59
Hamdoon Asim, Arnab Sain, Nauman Manzoor, Marium Nausherwan, Minaal Ahmed Malik, Fahad Hussain, Mohammad Bilal, Haris Khan, Amir Varasteh, Anushka Jindal, Mohammad Zain Sohail, Nadine Khayyat, Kanishka Wattage, Michele Halasa, Jack Song Chia, Justin Wilson. THE PREVALENCE OF SARCOPENIA AND ITS EFFECTS ON OUTCOMES IN POLYTRAUMA.....	60-65
Sergo Kobalava, Mikheil Tsverava, Eteri Tsetskhladze. CHRONIC HEART FAILURE WITH PRESERVED LEFT VENTRICLE EJECTION FRACTION (HFPEF) AND RIGHT VENTRICLE INVOLVEMENT IN PATIENTS WITH NORMAL SINUS RHYTHM AND ATRIAL FIBRILLATION; A SMALL OBSERVATIONAL STUDY: RELEVANCE OF THE PROBLEM, DIAGNOSTIC APPROACH, ECHOCARDIOGRAPHIC EVALUATION OF RIGHT VENTRICLE.....	66-74
Sergey V. Osminin, Fedor P. Vetshev, Ildar R. Bilyalov, Marina O. Astaeva, Yevgeniya V. Yeventyeva. PERIOPERATIVE FLOT CHEMOTHERAPY FOR GASTRIC CANCER: A RETROSPECTIVE SINGLE-CENTER COHORT TRIAL.....	75-81
Iskandar M. Alardi, Abbas AA. Kadhim, Ali SM. Aljanabi. PERONEUS LONGUS (PL) AUTOGRAFT IN ANTERIOR CRUCIATE LIGAMENT RECONSTRUCTION AS ALTERNATIVE GRAFT OPTION.....	82-84
Chayakova Akerke, Aiman Musina, Aldanysh Akbolat. TRENDS IN EMERGENCY MEDICAL CALLS BEFORE AND AFTER COVID-19 IN KAZAKHSTAN.....	85-91
Lipatov K.V, Komarova E.A, Solov'eva E.I, Kazantsev A.D, Gorbacheva I.V, Sotnikov D.N, Voinov M.A, Avdienko E.V, Shevchuk A.S, Sarkisyan I.P. MORE ON DEEP HEMATOMAS IN PATIENTS WITH COVID-19: CASE SERIES.....	92-99
Ling-Ling Zhou, Chu-Ying Gao, Jing-Jin Yang, Yong Liang, Lian-Ping He. CURRENT SITUATION AND COUNTERMEASURES OF TALENT TEAM CONSTRUCTION IN THE FIELD OF GRASSROOTS PUBLIC HEALTH.....	100-103
Arnab Sain, Urvashi Ghosh, Michele Halasa, Minaal Ahmed Malik, Nauman Manzoor, Jack Song Chia, Hamdoon Asim, Nadine Khayyat, Kanishka Wattage, Hoosai Manyar, Ahmed Elkilany, Anushka Jindal, Justin Wilson, Fahad Hussain, Hannah Burton, Wilam Ivanga Alfred, Vivek Deshmukh, Zain Sohail, Nirav Shah. USE OF TANTALUM CUP IN TOTAL HIP ARTHROPLASTY-A NARRATIVE REVIEW.....	104-106

Oula E. Hadi, Eman Hashim Yousif. HISTOLOGICAL EXAMINATION OF THE EFFECT OF URANIUM ON UDDER CELLS.....	107-115
Tchernev G, Pidakev I, Lozev I, Warbev M, Ivanova V, Broshtilova V. DERMATOLOGIC SURGERY: ROTATION ADVANCEMENT FLAP AS FIRST LINE TREATMENT FOR HIGH-RISK SQUAMOUS CELL CARCINOMAS OF THE PERIOCLAR/PERIORBITAL ZONE- PRESENTATION AND DISCUSSION ABOUT 2 NEW CASES.....	116-121
Osmalina M.K, Podchernyaeva N.S, Khachatryan L.G, Shpionkova O.V, Velikoretskaya M.D, Chebysheva S. N, Polyanskaya A.V, Gugueva E. A. STROKE AS A LIFE-THREATENING COMPLICATION IN CHILDREN WITH LINEAR SCLERODERMA OF FACE.....	122-128
D. Elgandashvili, Al. Kalantarov, T. Gugeshashvili. MAYER–ROKITANSKY–KUSTER–HAUSER SYNDROME. LAPAROSCOPIC SIGMOID VAGINOPLASTY FOR THE TREATMENT OF VAGINAL AGENESIS - SINGLE CENTER EXPERIENCE IN GEORGIA-CASE REPORT.....	129-138
Gocha Chankseliani, Merab Kiladze, Avtandil Girdaladze, Omar Gibradze. SUCCESSFUL EMERGENCY ARTERIAL EMBOLIZATION FOR MASSIVE GASTRODUODENAL BLEEDING IN HIGH-RISK PATIENT: CASE REPORT.....	139-142
Dildar MM. Mostafa, Mohammed T. Rasool. PREVALENCE OF OSTEOPOROSIS IN PATIENTS WITH RHEUMATOID ARTHRITIS IN IRAQI KURDISTAN /DUHOK GOVERNORATE.....	143-148
Arustamyan Makich, Guseynova Susanna V, Tyulekbayeva Diana, Tkhakokhova Liana A, Krivosheeva Yana V, Vasilev Semen A, Abbasova Zeinab I, Ponomareko Nadezhda O, Ismailova Sabina Z, Zakaev Israpil I. COMPARATIVE ANALYSIS OF HEPATOPROTECTORS IN WISTAR RATS WITH EXPERIMENTALLY INDUCED METABOLICALLY ASSOCIATED FATTY LIVER DISEASE.....	149-150
Jin Wu, Lan-Xi Wu, Kun Yan, Jun-You Li, Tao-Xiang Niu. ALOPECIA AREATA PROFILING SHOWS LNCRNAs REGULATE THE SUPPRESSED EXPRESSION OF KERATIN.....	151-159
Chkhaidze B, Loria L. EVALUATION OF THE FUNCTIONAL CHARACTERISTICS OF THE UNIVERSAL HEALTHCARE PROGRAM BY MEDICAL PERSONNEL IN TBILISI.....	160-164
Osmalina M.K, Podchernyaeva N.S, Khachatryan L.G, Shpionkova O.V, Polyanskaya A.V, Chebysheva S.N, Velikoretskaya M.D. JOINT LESIONS – COMMON EXTRACUTANEOUS MANIFESTATION IN JUVENILE LOCALIZED SCLERODERMA.....	165-172
Haval J. Ali, Zeki A. Mohamed, Dana A. Abdullah. HEALTH-RELATED QUALITY OF LIFE IN CHRONIC MYELOID LEUKAEMIA PATIENTS RECEIVING LONG-TERM THERAPY WITH DIFFERENT TYROSINE KINASE INHIBITORS IN KURDISTAN REGION.....	173-180
Arnab Sain, Ahmed Elkilany, Minaal Ahmed Malik, Nauman Manzoor, Nadine Khayyat, Hoosai Manyar, Michele Halasa, Jack Song Chia, Fahad Hussain, Hamdoon Asim, Kanishka Wattage, Anushka Jindal, Justin Wilson, Hannah Burton, Wilam Ivanga Alfred, Vivek Deshmukh, Zain Sohail. THE USE OF ANKLE BLOCK FOR ACUTE ANKLE FRACTURE REDUCTION: A REVIEW OF CURRENT LITERATURE.....	181-183
Megrelishvili Tamar, Mikadze Ia, Kipiani Nino, Mamuchishvili Nana, Bochorishvili Tea, Imnadze Tamar, Pachkoria Elene, Ratiani Levan. CLINICAL MANIFESTATION AND EPIDEMIOLOGICAL PECULIARITIES OF LEPTOSPIROSIS AT THE MODERN STAGE IN GEORGIA.....	184-187
Raikhan Bekmagambetova, Zulfiya Kachiyeva, Zhanat Ispayeva, Ildar Fakhradiyev, Maia Gotua, Roza Kenzhebekova, Aiganym Tolegenkyzy, Kristina Kovaleva, Gulbarash Turlugulova, Aigerim Zhakiyeva, Nazgul Janabayeva, Kunsulu Rysmakhanova. GENETIC ASSOCIATIONS WITH ASTHMA IN THE KAZAKH POPULATION: A CASE-CONTROL STUDY FOCUSING ON ACTN3 AND TSBP1 POLYMORPHISMS.....	188-194
Farah Saleh Abdul-Reda, Mohammed AH Jabarah AL-Zobaidy. EFFECTIVENESS AND TOLERABILITY OF APREMILAST IN TREATMENT OF A SAMPLE OF PATIENTS WITH PSORIASIS...	195-198
Emma Gevorkyan, Ruzanna Shushanyan, Karine Hovhannisyan, Marietta Karapetyan, Anna Karapetyan. ASSESSMENT OF CHANGES IN HEART RATE VARIABILITY INDICES OF STUDENTS AFTER COVID-19 LOCKDOWN: A COHORT STUDY.....	199-204
Alharbi Badr, Alwashmi Emad, Aloraini Abdullah Saleh, Almanian Ali Ibrahim, Alsuhailani Ali Abdullah, Aloraini Husam Yosuf, Alhwiriny Abdullah Nasser, Altwairgi Adil Khalaf. PERCEPTION OF UROLOGY SPECIALTY AND FACTORS INFLUENCE ITS CONSIDERATION AS A CAREER CHOICE AMONG MEDICALSTUDENTS.....	205-212
Tamuna Dundua, Vladimer Margvelashvili, Manana Kalandadze, Sopia Dalalishvili. THE ORAL HEALTH STATUS AND PREVENTIVE MEASUREMENTS FOR CANCER PATIENTS.....	213-217

## HISTOLOGICAL EXAMINATION OF THE EFFECT OF URANIUM ON UDDER CELLS

Oula E. Hadi<sup>1\*</sup>, Eman Hashim Yousif<sup>2</sup>.

<sup>1,2</sup>Department of pathology and poultry disease, College of Veterinary Medicine, University of Baghdad, Iraq.

### Abstract.

The addressing this question in udder tissue (main target of the metal) and test here if uranium U at low concentrations could also be a pro-oxidant. The research deals with different groups of grass-fed cows in several locations where the same phenomenon represents a case from Basra/Iraq. The histopathological examination of the udder in cows with (U) revealed hemangiomas transformation. For the uranium, experts used a sodium iodide instrument to perform measurements and analyzed samples of cow udders as these organs are most affected by uranium. The tissues were being inflamed and they would die, becoming degenerated and necrotic (inflammatory). But, if given in high doses leads to the formation of different tumors: GGFL (gentle giants famous large udders) or clear cell carcinoma, Sarcomatoid type RCC. There is toxic uranium in the levels of grass that cattle consume and as a result there) cause defense allergies prevail over cows it is easy to induce oxidative pressure within their udders. However, even under (U) doses restraint stressors are seldom found to have additional negative effects at baseline value but the additive influence of these is never ruled out.

**Key words.** Effect of uranium on the udder, histological study, cell carcinoma, pro-oxidant activity of uranium (U).

### Introduction.

Uranium is a naturally occurring element that can be easily found in the earth's crust [1]. This highly toxic radioactive heavy metal is one of the most stringent pollution issues [2]. Given the increasing exposure of uranium products through oral and inhalational intake, together with its potentially harmful effects on humans as well as animals, an in-depth analysis regarding distribution and toxicity assays is mandatory. There are three isotopes of natural uranium: U234, U235, and, finally, the most abundant one, which accounts for about 99% of all uses in everyday life is U238. Although these two isotopes are distinguished from each other by their radioactive behavior, they have similar chemical properties [3-4].

One important method that uranium can contaminate animals with radionuclides is through their consumption of food, water, or soil [5-7]. The known negative effects of uranium exposure from investigations and work-related exposures include chemically induced udder toxicity, bladder damage, and lung cancer from exposure to radon, which is produced by radioactive decay [8-10].

Renal failure and injury to the proximal tubules may result from the location of the uranium accumulation in the tubules [11-15]. Moreover, numerous authors have shown that the liver [16], the central nervous system [14,15], and the gastrointestinal tracts [13] are among the other biological targets of acute and chronic exposure to low uranium levels that have been shown to change. Basrah Province is the main area in Iraq where uranium

pollution is present. This study looked at the histopathological effects of uranium residues on cow udder samples from the province of Basrah.

### Materials and Methods.

Udder samples of cows (n=100) were collected from the agricultural fields where these animals were raised.

The samples were cut, grilled, and exposed to the sun for a while before being dried in an oven at 70°C for an entire night. They were then ground into a fine powder and kept in Marinelli beakers for a month. Finally, it was analyzed using a NaI gamma spectrometer (TI) with the (3×3) crystal area.

### The Biological activity Determinants:

The following equation is used to calculate biological activity [17].

$$(A) \times (Bq/Kg) \times \frac{NET}{E * I_g * m * t} =$$

Assuming (t) is the measurement period (86400 sec), where A is the sample's specific activity, also the (NET) is the area under the peak, where the (E) is the detection efficiency, and the symbol (Kg) is the sample's mass in kilograms.

The study was conducted in four different locations in the city of Basrah, where Uranium concentrations were studied in the four locations—100 samples for all locations. According to the concentrations of site N were 40 samples, site E was 20 samples, site W was 20 samples, and site S was 20 samples.

### Histopathological study.

The tissue samples taken from the cow's udder were preserved in a 10% formaldehyde solution for fixation before being routinely processed with a histokine. Tissue slices were embedded in paraffin blocks, sectioned with a microtome, stained with hematoxylin and eosin, and examined under a light microscope to record the histological changes [18-22].

### Results and Discussion.

The present study discussed the cancerous lesions of the udders in cows, The connection of udder cells with different types of cancers as a result of their being affected individually or simultaneously by radioactive levels of radioactive uranium isotopes, causing cellular toxicity at first, then the matter turns and then develops later to the occurrence of genetic transfers in which DNA and RNA are exposed to new dissolutions and connections that lead to the occurrence of genetic swelling at first, then it turns later into cancerous tumors that affect the udders with cancer [23-27].

The tumor consists of malignant duct-lining cells disposed of in udder tubes, solid cell collation, glands, and anastomosing masses.

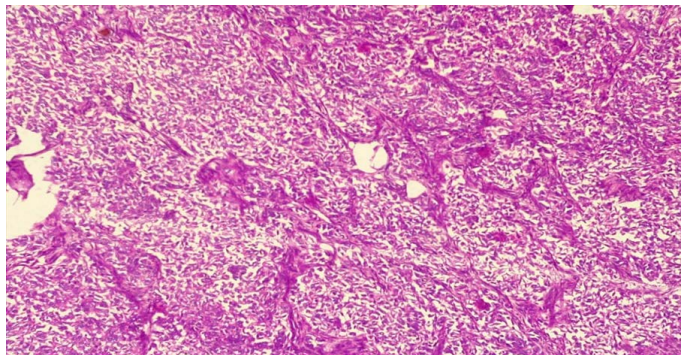


Cancer cells penetrate the connective tissue, and these cells are embedded within a dense fibrous content [28-32].

It consists of strands of infiltrating tumor cells, loosely dispersed throughout the fibrous matrix, the cells are small and uniform staining with relatively little cytologic pleomorphism, irregularly shaped, and the tumor cells are arranged in concentric rings.

Collagen fibers are in close contact with endothelial cell collagen that typically causes Adino carcinoma of the udder: A cancerous cell is characterized by a large nucleus, having irregular size and shape, the nucleoli are prominent, the cytoplasm is scarce and intensely colored, or on the contrary is pale [33-36].

As in Figure 1, it appears that cancer cells vary in different shapes. They are either small cells with regular nuclei in a darker, clearer color, or they are large cells containing large nuclei. The latter are irregular and also dark in color, and these cells invade the spaces surrounding the vessels. Blood and nerve cells, and the tumor cells multiply and appear to form dark blue-colored fibers upon staining, as shown in Figure 1.



**Figure 1.** Invasive ductal carcinoma of the udder in the early stages of tumor formation.

The tumor consists of primitive malignant ductal endothelial cells. They are scattered in cords, nests of solid cells, tangled masses, and heavier mixtures.  $x = 10$ .

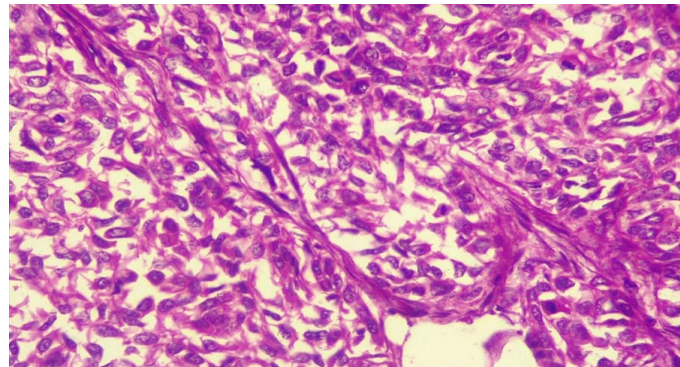
The classification of stages varies from one type of cancer to another, but in general, the TNM system is used as follows:

Tumor (T), the letter T is added to a number from (0-4) to indicate the size of the tumor and the extent of its spread to the surrounding tissues, so that the larger the tumor and its spread, the higher the number is given, i.e. T0 indicates that there is no measurable tumor.

Nodes (N), the letter N is added to a number from (0-3) to indicate whether the cancer has spread to the lymph nodes or not, and the lymph nodes close to the tumor are called local nodes (regional), and the other nodes are called distant nodes (distant). The degree of spread increases with the increase in the number, for example, N0 means that there is no spread of cancer cells to the lymph nodes, but in some types of cancer, the letter N indicates the location of the lymph nodes affected by cancer instead of their number.

Figures 1 to 4 represent the stages of the disease from the early stages until its development and the appearance of the infected tissues clearly under the duct.

It is clear that cancer cells invade the connective tissue stroma, and the cytological details of cancer cells vary from small cells with normal, hyperchromatic nuclei at a distance to large cells with large, irregular, hyperchromatic bands with division at high energy (high mitotic index)  $x = 40$ , show in Figure 2.



**Figure 2.** Invasive ductal carcinoma of the udder in the high concentration of uranium.

For metastasis (M), the letter M is added to the number 0 or 1 to indicate whether the cancer has spread to other parts of the body or not, where M0 means that the cancer has not spread, and M1 means that it has spread.

For example, a small cancerous tumor that has spread to the lymph nodes but not to other organs may be given the symbol (T2 N1 M0), and another advanced tumor that has spread to the nodes and other parts of the body may be given the symbol (T4 N3 M1). Researchers may use other letters such as (a, b, c, m) before the classification letters to give additional details about the tumor, for example, lung cancer of stage M1a is cancer that began in one lung and has spread to the other, while stage M1b indicates that the cancer has spread from the lung to other parts of the body. In addition to these classifications, other factors are taken into account when determining the stage of cancer in this system, including:

#### **Grade:**

This factor describes the degree of similarity in the appearance of cancer cells to normal cells when viewed under a microscope, it may be indicated by placing the letter G followed by one of the numbers (0-4). Normal tissues contain many types of cells combined together, if cancerous tissues resemble normal tissues and contain several types of cells, they are called differentiated, and the tumor is described as low-grade tumor. If the cancerous tissue appears completely different from normal tissues, it is called poorly differentiated and is described as a high-grade tumor. The grade of the tumor helps predict the speed at which it is likely to spread, so the lower its grade, the better the expected results.

#### **Tumor markers or biomarkers:**

Tumor markers or biomarkers Are substances found in high levels on the surface of cancer cells or in the blood, urine, or body tissues of Animals with tumors These markers give a good prediction of how far cancer can spread and help determine the best treatment methods. In some types of cancer, these markers may even be better than knowing the stage in determining treatment.

**Tumor genetics:**

Researchers have been able to find ways to help them identify the genes responsible for the development of many types of cancer, which helps predict whether a certain type of tumor will spread or not, and determine the best treatment methods for this tumor, which helps doctors find a treatment tailored to each case.

**Number staging systems:**

Specialists combine the results of the TNM system with other factors specific to the type of cancer to determine the cancer stage numerically for each patient, which includes stages (1-4) and sometimes stage zero is used.

**Stage zero (Stage 0):**

This stage describes the tumor in situ, meaning that it remained in its place of growth and did not spread to the surrounding tissues. This tumor usually has a high curability, by surgically removing the entire tumor. The tumor at this stage is not cancerous in the beginning, but it may develop into a cancerous tumor in the future.

These tumors are often difficult to detect during examinations due to their small size unless they are in visible areas such as the skin. They can also be detected in some areas, such as the chest and cervix, through some examinations.

**Stage I:**

The tumor at this stage is small and located where it started and has not grown deeply into the surrounding tissues and has not spread to the lymph nodes or any other parts of the body. This is usually called the early-stage cancer stage.

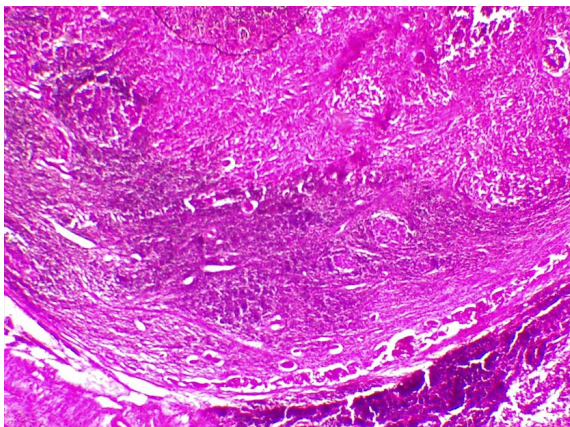
**Stages II and III:**

The tumor at these stages is generally large and growing to varying degrees in the surrounding tissues. It may have spread to nearby lymph nodes, but has not spread to other parts of the body.

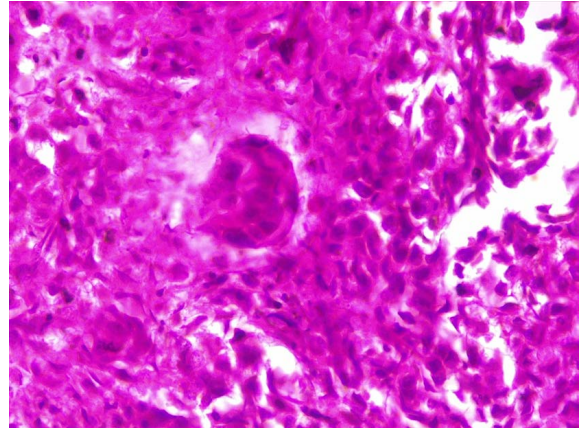
**Stage IV:**

Means that the cancer has spread to other organs or parts of the body. This is called the advanced stage or metastatic cancer.

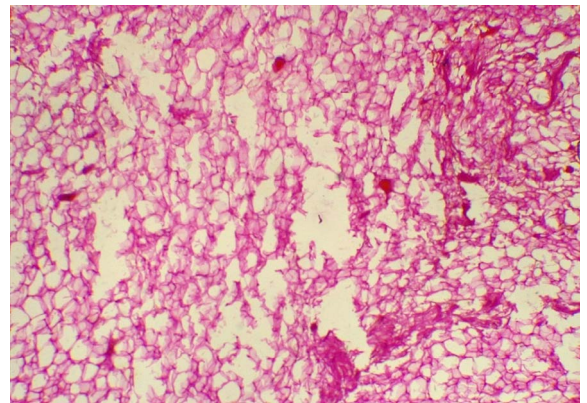
Cells have scant cytoplasm tapering elongated dark nuclei with increased granular chromatin Variable nucleoli, mitotic activity Present with abnormal forms Variable collagen, X = 40, show in Figures 3-8.



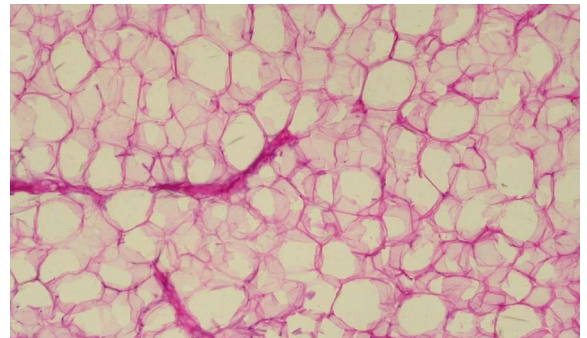
**Figure 3.** Invasive ductal carcinoma of udder; x=10.



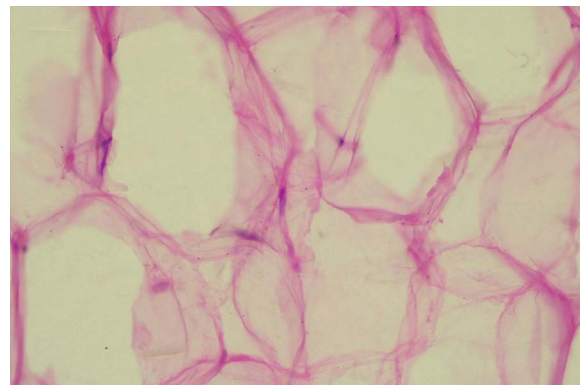
**Figure 4.** Invasive ductal carcinoma of udder X=40.



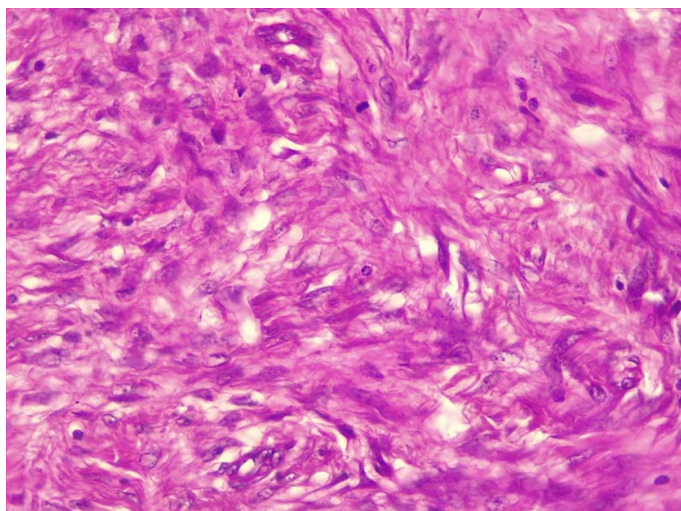
**Figure 5.** Lipoma of udder in low concentration of uranium, benign adipose tissue arrangement, empty cytoplasm x=10.



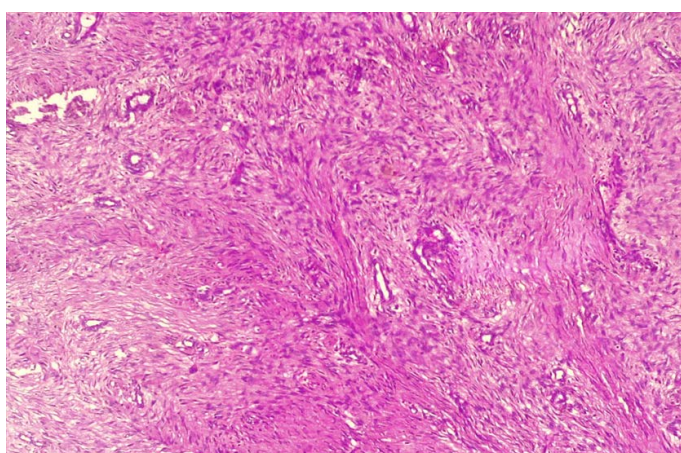
**Figure 6.** Lipoma of udder growth pattern of adipose tissue x=40.



**Figure 7.** Fat cells with empty cytoplasm and an extrinsic nuclei X=40.



**Figure 8.** Udder fibrosarcoma of the udder.



**Figure 9.** Udder fibrosarcoma, the udder is highly cellular fibroblastic in proliferation in a herringbone pattern (Ceus in columns of short parallel lines with all lines in one column sloping one wag, and lines in adjacent columns sloping the other wag).  $x = 10$ , show in figure 9.

Tumor mode cells in renal cancer with clear cell appearance are transparent. Tiny blood arteries that supply the tumor with copious amounts of blood frequently divide the tumor cell clusters. Chromophobe renal cell carcinoma is the opposite pathological disorder. It is a solid tumor of pale, granular cells with noticeable borders. Lastly, reticular cytoplasm perinuclear halos and wrinkled hyperchromatic nuclei are also observed in renal cell cancer sarcomatoid, which exhibits cellular atypia and a loss of typical epithelial hightcellularity [37-41].

Numerous short- and long-term studies have demonstrated the toxicity of uranium to both people and animals. It is widely acknowledged that the udder is the primary organ at risk for damage from heavy metal poisoning, with the proximal convoluted tubules bearing most of the damage. Our goal is to ascertain whether uranium-induced udder damage progresses in terms of histopathology research. In the udder of a cow with decreased uranium content, we saw vacuolation of the renal tubules, lobulated glomeruli infiltrations with intestinal fibrosis, and inflammatory cell infiltrations.

Lesions showed signs of severe fibrosis and renal capsule invasion by mononuclear cells at higher concentrations.

Many forms of renal cell cancers were discovered in areas with elevated uranium contents. The tumor in clear renal cell carcinoma comprises giant, spherical cells that join together to form enormous cell clusters. Many tumor cells had distinct cytoplasmic or cell bodies, and the clusters of cells were frequently divided by microscopic blood veins that supplied the tumor with copious amounts of blood (Figure 3). A solid tumor of granular pale cells with pronounced halos and wrinkled hyperchromatic nuclei was identified as chromophobe renal cell carcinoma. Sarcomatoid renal cell carcinoma also exhibited spindle cells, high cellularity, cellular atypia, and the absence of typical epithelial components.

Our research showed that uranium caused significant pathological alterations in cows' udders. According to the research, exposure to uranium mainly affect the udders, the leading cause of death is renal insufficiency [42-47]. Following uranium injection, inhalation, or ingestion, inflammation is characterized as a harmful mechanism; nevertheless, there are few papers discussing its role in uranium nephrotoxicity. Despite the significant role, the inflammatory processes play a role in udder injury [48-53].

NF and KB activation was shown to elicit an inflammatory response in acutely exposed rats, and the transcriptome investigation observed the upregulation of three inflammatory genes, including osteopontin (opn), Pecam, and Gal-3, in mouse udders exposed to uranium. The inflammatory increase of intracellular and vascular cell adhesion molecules (ICAM) and VCAM generated by uranium facilitates the recruitment of inflammatory cells to the udder. The organ most vulnerable to uranium poisoning is the udder, and it is widely known that uranium damages and malfunctions this organ, leading to either acute or chronic renal illness [54-56]. Chronic oxidative stress, inflammation, DNA damage, and cell death are the leading causes of uranium-induced renal impairment. Elevated urine glucose, protein, and electrolyte excretion indicate renal impairment. (Calcium, magnesium, sodium, potassium, and inorganic phosphate). Most likely due to decreased reabsorption from the proximal tubules or changed renal cell transport properties [56-58].

Based on the exposure route and the molecule's solubility, uranium has been classified as carcinogenic in several experimental investigations. One description of carcinogenesis is as a step event. The first step involves the direct and indirect mutation of udder cells' DNA [59,60], which turns them from healthy cells into possibly cancerous ones. After uranium exposure, DDR processes are presumably compromised, leading to an accumulation of nuclear DNA modification that facilitates their proliferation [61,62].

## Conclusion and Recommendations.

The effect of uranium present in the content of herbs fed to cows in different areas of the city of Basra was studied, and the health and tissue effects on the udders of cows fed on these herbs were studied. Uranium levels were measured using a sodium iodide device, and samples were taken from the cows' udders, as they are the organ most affected by uranium. If low concentrations of uranium are taken, there are cases of tissue inflammation, but in high doses they lead to the occurrence of

various tumors in the udders. The study's findings suggest that uranium levels in herbs cause cows' antioxidant defense systems to weaken and increase oxidative stress in their udders.

Various udder tumors have been reported as a result of uranium exposure, and these tumors are the most common among domestic animals such as cattle that have been grazing in areas close to depleted uranium deposits. Common tumors that frequently occur in the udders of domestic animals include equine sarcoidosis, squamous cell carcinoma, lymphoma, melanoma, basal cell tumor, papilloma, and mast cell tumor. Udder tumors are diagnosed more frequently than other tumors because the udder is constantly exposed to various environmental carcinogens. Therefore, primary udder tumors and other types of tumors in cattle should be studied and grouped together in a single document. The lesions should be carefully diagnosed based on clinical manifestations, cytology, and histopathology. Immunohistochemistry, radiology, and ultrasound should also be used in veterinary clinics to diagnose udder tumors in cattle.

#### Authors' Collaboration.

All authors collaborated in collecting biostatistical data and then studied the aims of the manuscript and how to write the manuscript and make it more clear to the reader.

#### Source of Financial Funding.

There is no source of financial funding, but the authors paid the costs of laboratory work, laboratory materials, and other dues.

**Disclaimer:** The authors may provide all data and results obtained.

**Announcement:** The Ethical Committee of the College of Veterinary Medicine, University of Baghdad approved the study. The authors declare that there is no conflict of interest in the manuscript.

#### REFERENCES

1. Veterinary Cancer Society (VCS). Carcinogens. 2012. <http://vetcancersociety.org>.
2. Snashall D, Patel D. ABC of Occupational and Environmental Medicine. 2nd ed. BMJ Group. London. 2003;61.
3. Ettinger S. J. Textbook of Veterinary Internal Medicine. W. B. Saunders Comp. USA. 1993;222.
4. Cuney M. The extreme diversity of uranium deposits. Mineralium Deposita. 2009;44:3-9.
5. Zou W, Hongjuan B, Lei Z, et al. Characterization and properties of zeolite as absorbent for removal of uranium (VI) from solution in fixed Bed Column. Journal of Radioanalytical and Nuclear Chemistry. 2011;288:779-788.
6. Atsdr. Agency for toxic substances and disease registry. Toxicological profile for uranium (update) Atlanta, Georgia, USA: U.S. Department of Health and Human Services, Public Health Service. 1999.
7. U. S. D. A Agricultural hand book, No, 60 Washington Government printing office Aug. 1969:71.
8. R. H. Hadad. Hydrogeology of Safwan area. South Iraq, Ph. D. Thesis, Dept. of Geology, Univ, of London. 1978.
9. Harry BP, Urban JB. Effect of Agriculture land use on ground water quality in a small pennsylvanian water shed Ground water J. 1985;2:68-80.
10. Brugge D, de Lemos J. L, Oldmixon B. Exposure pathway and health effects associated with chemical and radiological toxicity of natural Uranium: A review. Rev. Environ. Health. 2005;20:177-193.
11. Mohammed B, Nasif RM, Al-Bayati AT. Determination of Radionuclides concentrations in soil around of AL-Tuwaita nuclear research center in Iraq by using gamma spectroscopy analysis system. Journal of Chemical, Biological and Physical Sciences. 2016;6:996-1005.
12. Neamah GAK, Yousif EH. Determination of Depleted uranium concentration and histopathological changes in local Iraqi fish and chickens. The Iraqi Journal of Veterinary Medicine. 2019;43:86-97.
13. International Atomic Energy Agency. Hand book of parameter values for the predication of radionuclide transfer in terrestrial and freshwater environments, Technical Reports Series. 2010;472:194.
14. Gilliland F.D, Hunt W.C, Pardilla M, et al. Uranium mining and lung cancer among Navajo men New Mexico and Arizona, 1969 - 1993. J. Occup. Environ. Med. 2000;42:278-283.
15. Mulloy K.B, James D. S, Mohs K, et al. Lung cancer in a non smoking underground uranium miner. Environ. Health Perspect. 2001;109:305-309.
16. Chen J, Meryehof D.P, Tracy B.L. Model results of udder burdens from uranium intakes. Health Phys. 2004;86:3-11.
17. Saleh AF, Elias MM, Tawfiq NF. Determination of Uranium Concentration in urine of workers in an Iraqi phosphate mine and fertilizer plants. J. Radioanal Nucl. Chem. 2013;298:187-193.
18. Homma-takeda S, Kitahora K, Suzuki K, et al. cellular localization of uranium in the renal proximal tubules during acute renal uranium toxicity. J. Appl. Toxicol. 2015;35:1594-1600.
19. Vijayan SP, Rekha P.D, Dinesh U, et al. Biochemical and histopathological response of the Swiss albino micre treated with uranyl and its recovery. Renal Failure. 2016;38:770-775.
20. Dublineau I, Grandcolas L, Grison S, et al. Modifications of inflammatory pathways in Rat intestine following chronic ingestion of depleted uranium. Toxicological Sciences. 2007;98:458-468.
21. Lestaevel P, Bussy C, Paquet F. Changes in sleep wake cycle after chronic exposure to uranium in rats. Neurotoxicology and Teratology. 2005;27:835-840.
22. Houpert P, Frelon S, Monleau M, et al. Heterogenous accumulation of uranium in the brain of rats. Radiat Prot. Dosimetry. 2007;127:86-89.
23. Souidi M, Gueguen Y, Linard C, et al. In vitro effects of chronic contamination with depleted uranium on CYP3A and associated nuclear receptors PXR and CAR in the rat. Toxicology. 2005;214:113-122.
24. Bansiwat S.K, Dadhich H, Rakhi K. Pathological observations of Glomerulonephritis in indigenous cattle in Rajasthan. International Journal of Cow Science. 2006;2:29-33.
25. Al-Tae F. S. Pathological and Cytogenetic study on some epithelial skin tumors of Human and Bovine. Msc. Vet. Med. coll. Uni. Baghdad. 2003.
26. International Atomic Energy Agency (IAEA). Featur: Depleted Uranium. Vienna. Austria. 2013.
27. Al-Rawi N, Yas R, Tawfiq N, et al. Determination of Uranium concentration in sheep Organs for some Iraqi cities. J. Bagdad Science. 2011;8:766-771.

28. Tuhvalshin R, Hadjamberdiev I, Bikhovchenko J. Uranium Pollution of meat in Tien-Shan. NATO science for peace and security series, series C. Environmental security. 2008;193-197.
29. Neamah G, Yousif E, Anees A, et al. Accumulation of chronic uranyl nitrate hexahydrate in udders and histopathology in adult albino rats. *OJVR*. 2019;23:1095-1103.
30. Mahdi K, Subhi A, Sharif NR, et al. Determination of Radon Concentrations in Soil Around Al-Tuwaitha Site Using CR-39 Detector. *Engineering and Technology Journal*. 2018;36:108-112.
31. Rozell L.E, Hahn F. F, Lee R. B, et al. Assessing the renal toxicity of capstone depleted uranium oxides and other uranium compound. *Health Phys*. 2009;96:343-351.
32. Al-Awadi AQ, Alwan MJ. The influence of whole sonicated pseudomonas aeruginosa antigens on experimental p. Aeruginosa arthritis in rabbits. *The Iraqi Journal of Veterinary Medicine*. 2014;38:1-10.
33. Cheng K.L, Hogan A.C, Parvy D.L, et al. Uranium toxicity and speciation during chronic exposure to the tropical freshwater fish, *Mogurnda mogurnda*. *Chemosphere*. 2010;79:547-554.
34. Monleau M, De Méo M, Paquet F, et al. Genotoxic and inflammatory effects of depleted uranium particles inhaled by rats. *Toxicol. Sci*. 2006;89:287-295.
35. Al-Hamadany WS, AL-Ubaidi KHM, AL-Bayati ATS, et al. Detection of Radiation Pollution with Depleted Uranium in some Iraqi Cattle With Cancer and their Field Soils. *International journal of advanced Research*. 2013;1:7-11.
36. Orona N, Tasat D. Uranyl nitrate-exposed rat alveolar macrophages cell death: Influence of superoxide anion and TNF alpha mediators. *Toxicol. Appl. Pharmacol*. 2012;261:309-316.
37. Zheng J, Zhao T, Yuan Y, et al. Hydrogen sulfide (H<sub>2</sub>S) attenuates uranium-induced acute nephrotoxicity through oxidative stress and inflammatory response via Nrf2-NF-kappaB pathways. *Chem. Biol. Interact*. 2015;242:353-362.
38. Yi J, Yuan Y, Zheng J, et al. Hydrogen sulfide alleviates uranium-induced udder cell apoptosis mediated by ER stress via 20S proteasome involving in Akt/GSK-3beta/Fyn-Nrf2 signaling. *Free Radic. Res*. 2018;52:1020-1029.
39. Taulan M, Paquet F, Argiles A, et al. Comprehensive analysis of the renal transcriptional response to acute uranyl nitrate exposure. *BMC Genom*. 2006;7:2.
40. Ferenbach D.A, Bonventre J.V. Mechanisms of maladaptive repair after AKI leading to accelerated udder ageing and CKD. *Nat. Rev. Nephrol*. 2015;11:264-276.
41. Taulan M, Paquet F, Argiles A, et al. Comprehensive analysis of the renal transcriptional response to acute uranyl nitrate exposure. *BMC Genom*. 2006;7:2.
42. Bontemps A, Conquet L, Elie C, et al. In vivo Comparison of the Phenotypic Aspects and Molecular Mechanisms of Two Nephrotoxic Agents, Sodium Fluoride and Uranyl Nitrate. *Int. J. Environ. Res. Public Health*. 2019;16:1136.
43. UNSCEAR. Sources, Effects and Risks of Ionizing Radiation, United Nations Scientific Committee on the Effects of Atomic Radiation (UNSCEAR) 2016 Report; UNSCEARU: New York, NY, USA. 2016.
44. Guéguen Y, Roy L, Hornhardt S, et al. Biomarkers for Uranium Risk Assessment for the Development of the CURE (Concerted Uranium Research in Europe) Molecular Epidemiological Protocol. *Radiat. Res*. 2017;187:107-127.
45. Haley D.P, Bulger R.E, Dobyen D.C. The long-term effects of uranyl nitrate on the structure and function of the rat udder. *Virchows Arch. B Cell Pathol. Incl. Mol. Pathol*. 1982;41:181-192.
46. Diamond G.L, Morrow P.E, Panner B.J, et al. Reversible uranyl fluoride nephrotoxicity in the Long Evans rat. *Fundam. Appl. Toxicol*. 1989;13:65-78.
47. Tawfiq NF, Yas RM, Alrawi NB, et al. Determination of Uranium Concentration in Sheep Organs for some Iraqi Cities. *Baghdad Science Journal*. 2011;8:766-771.
48. Haley D.P, Bulger R.E, Dobyen D.C. The long-term effects of uranyl nitrate on the structure and function of the rat udder. *Virchows Arch. B Cell Pathol. Incl. Mol. Pathol*. 1982;41:181-192.
49. Banday A.A, Priyamvada S, Farooq N, et al. Effect of uranyl nitrate on enzymes of carbohydrate metabolism and brush border membrane in different udder tissues. *Food Chem. Toxicol*. 2008;46:2080-2088.
50. Bontemps A, Conquet L, Elie C, et al. In vivo Comparison of the Phenotypic Aspects and Molecular Mechanisms of Two Nephrotoxic Agents, Sodium Fluoride and Uranyl Nitrate. *Int. J. Environ. Res. Public Health*. 2019;16:1136.
51. Taulan M, Paquet F, Argiles A, et al. Comprehensive analysis of the renal transcriptional response to acute uranyl nitrate exposure. *BMC Genom*. 2006;7:2.
52. Sánchez D.J, Bellés M, Albina M.L, et al. Nephrotoxicity of simultaneous exposure to mercury and uranium in comparison to individual effects of these metals in rats. *Biol. Trace Elem. Res*. 2001;84:139-154.
53. Cappello F, Macario A.J.L. Depleted uranium induces human carcinogenesis involving the immune and chaperoning systems: Realities and working hypotheses. *Med. Hypotheses*. 2019;124:26-30.
54. Asic A, Kozaric A, Besic L, et al. Chemical toxicity and radioactivity of depleted uranium: The evidence from in vivo and in vitro studies. *Environ. Res*. 2017;156:665-673.
55. Yellowhair M, Romanotto M.R, Stearns D.M, et al. Uranyl acetate induced DNA single strand breaks and AP sites in Chinese hamster ovary cells. *Toxicol. Appl. Pharmacol*. 2018;349:29-38.
56. Yazzie M, Gamble S.L, Civitello A.E.R, et al. Uranyl acetate causes DNA single strand breaks in vitro in the presence of ascorbate (vitamin C). *Chem. Res. Toxicol*. 2003;16:524-530.
57. Hamilton M.M, Ejniak J.W, Carmichael A.J. Uranium reactions with hydrogen peroxide studied by EPR-spin trapping with DMPO. *J. Chem. Soc. Perkin Trans*. 1997;12:2491-2494.
58. Periyakaruppan A, Kumar F, Sarkar S, et al. Uranium induces oxidative stress in lung epithelial cells. *Arch. Toxicol*. 2006;81:389-395.
59. Wise S.S, Thompson W.D, Aboueissa A.-M, et al. Particulate depleted uranium is cytotoxic and clastogenic to human lung cells. *Chem. Res. Toxicol*. 2007;20:815-820.
60. Holmes A.L, Joyce K, Xie H, et al. The impact of homologous recombination repair deficiency on depleted uranium clastogenicity in Chinese hamster ovary cells: XRCC3 protects cells from chromosome aberrations, but increases chromosome fragmentation. *Mutat. Res. Mol. Mech. Mutagen*. 2014;762:1-9.

61. Al-Mashhadani AH. Assessment of radiological risk in the areas around surface disposal at AL- Tuwaitha site. Iraqi Journal of Physics. 2016;14:90-97.

62. Alwan AM, Al-Bayati AT, Mahdi KH, et al. Calculation of Radiation Nuclei Concentrations in Fertilized and Unfertilized Plants Samples Using Gamma Spectroscopy, NeuroQuantology. 2021;19:13-18.



