

GEORGIAN MEDICAL NEWS

ISSN 1512-0112

NO 9 (354) Декабрь 2024

ТБИЛИСИ - NEW YORK



ЕЖЕМЕСЯЧНЫЙ НАУЧНЫЙ ЖУРНАЛ

Медицинские новости Грузии
საქართველოს სამედიცინო სიახლენი

GEORGIAN MEDICAL NEWS

Monthly Georgia-US joint scientific journal published both in electronic and paper formats of the Agency of Medical Information of the Georgian Association of Business Press.
Published since 1994. Distributed in NIS, EU and USA.

GMN: Georgian Medical News is peer-reviewed, published monthly journal committed to promoting the science and art of medicine and the betterment of public health, published by the GMN Editorial Board since 1994. GMN carries original scientific articles on medicine, biology and pharmacy, which are of experimental, theoretical and practical character; publishes original research, reviews, commentaries, editorials, essays, medical news, and correspondence in English and Russian.

GMN is indexed in MEDLINE, SCOPUS, PubMed and VINITI Russian Academy of Sciences. The full text content is available through EBSCO databases.

GMN: Медицинские новости Грузии - ежемесячный рецензируемый научный журнал, издаётся Редакционной коллегией с 1994 года на русском и английском языках в целях поддержки медицинской науки и улучшения здравоохранения. В журнале публикуются оригинальные научные статьи в области медицины, биологии и фармации, статьи обзорного характера, научные сообщения, новости медицины и здравоохранения. Журнал индексируется в MEDLINE, отражён в базе данных SCOPUS, PubMed и ВИНТИ РАН. Полнотекстовые статьи журнала доступны через БД EBSCO.

GMN: Georgian Medical News – საქართველოს სამედიცინო სიახლენი – არის ყოველთვიური სამეცნიერო სამედიცინო რეცენზირებადი ჟურნალი, გამოიცემა 1994 წლიდან, წარმოადგენს სარედაქციო კოლეგიისა და აშშ-ის მეცნიერების, განათლების, ინდუსტრიის, ხელოვნებისა და ბუნებისმეტყველების საერთაშორისო აკადემიის ერთობლივ გამოცემას. GMN-ში რუსულ და ინგლისურ ენებზე ქვეყნდება ექსპერიმენტული, თეორიული და პრაქტიკული ხასიათის ორიგინალური სამეცნიერო სტატიები მედიცინის, ბიოლოგიისა და ფარმაციის სფეროში, მიმოხილვითი ხასიათის სტატიები.

ჟურნალი ინდექსირებულია MEDLINE-ის საერთაშორისო სისტემაში, ასახულია SCOPUS-ის, PubMed-ის და ВИНТИ РАН-ის მონაცემთა ბაზებში. სტატიების სრული ტექსტი ხელმისაწვდომია EBSCO-ს მონაცემთა ბაზებიდან.

WEBSITE

www.geomednews.com

К СВЕДЕНИЮ АВТОРОВ!

При направлении статьи в редакцию необходимо соблюдать следующие правила:

1. Статья должна быть представлена в двух экземплярах, на русском или английском языках, напечатанная через **полтора интервала на одной стороне стандартного листа с шириной левого поля в три сантиметра**. Используемый компьютерный шрифт для текста на русском и английском языках - **Times New Roman (Кириллица)**, для текста на грузинском языке следует использовать **AcadNusx**. Размер шрифта - **12**. К рукописи, напечатанной на компьютере, должен быть приложен CD со статьей.

2. Размер статьи должен быть не менее десяти и не более двадцати страниц машинописи, включая указатель литературы и резюме на английском, русском и грузинском языках.

3. В статье должны быть освещены актуальность данного материала, методы и результаты исследования и их обсуждение.

При представлении в печать научных экспериментальных работ авторы должны указывать вид и количество экспериментальных животных, применявшиеся методы обезболивания и усыпления (в ходе острых опытов).

4. К статье должны быть приложены краткое (на полстраницы) резюме на английском, русском и грузинском языках (включающее следующие разделы: цель исследования, материал и методы, результаты и заключение) и список ключевых слов (key words).

5. Таблицы необходимо представлять в печатной форме. Фотокопии не принимаются. **Все цифровые, итоговые и процентные данные в таблицах должны соответствовать таковым в тексте статьи**. Таблицы и графики должны быть озаглавлены.

6. Фотографии должны быть контрастными, фотокопии с рентгенограмм - в позитивном изображении. Рисунки, чертежи и диаграммы следует озаглавить, пронумеровать и вставить в соответствующее место текста **в tiff формате**.

В подписях к микрофотографиям следует указывать степень увеличения через окуляр или объектив и метод окраски или импрегнации срезов.

7. Фамилии отечественных авторов приводятся в оригинальной транскрипции.

8. При оформлении и направлении статей в журнал МНГ просим авторов соблюдать правила, изложенные в «Единых требованиях к рукописям, представляемым в биомедицинские журналы», принятых Международным комитетом редакторов медицинских журналов - <http://www.spinesurgery.ru/files/publish.pdf> и http://www.nlm.nih.gov/bsd/uniform_requirements.html В конце каждой оригинальной статьи приводится библиографический список. В список литературы включаются все материалы, на которые имеются ссылки в тексте. Список составляется в алфавитном порядке и нумеруется. Литературный источник приводится на языке оригинала. В списке литературы сначала приводятся работы, написанные знаками грузинского алфавита, затем кириллицей и латиницей. Ссылки на цитируемые работы в тексте статьи даются в квадратных скобках в виде номера, соответствующего номеру данной работы в списке литературы. Большинство цитированных источников должны быть за последние 5-7 лет.

9. Для получения права на публикацию статья должна иметь от руководителя работы или учреждения визу и сопроводительное отношение, написанные или напечатанные на бланке и заверенные подписью и печатью.

10. В конце статьи должны быть подписи всех авторов, полностью приведены их фамилии, имена и отчества, указаны служебный и домашний номера телефонов и адреса или иные координаты. Количество авторов (соавторов) не должно превышать пяти человек.

11. Редакция оставляет за собой право сокращать и исправлять статьи. Корректур авторам не высылаются, вся работа и сверка проводится по авторскому оригиналу.

12. Недопустимо направление в редакцию работ, представленных к печати в иных издательствах или опубликованных в других изданиях.

При нарушении указанных правил статьи не рассматриваются.

REQUIREMENTS

Please note, materials submitted to the Editorial Office Staff are supposed to meet the following requirements:

1. Articles must be provided with a double copy, in English or Russian languages and typed or computer-printed on a single side of standard typing paper, with the left margin of 3 centimeters width, and 1.5 spacing between the lines, typeface - **Times New Roman (Cyrillic)**, print size - 12 (referring to Georgian and Russian materials). With computer-printed texts please enclose a CD carrying the same file titled with Latin symbols.

2. Size of the article, including index and resume in English, Russian and Georgian languages must be at least 10 pages and not exceed the limit of 20 pages of typed or computer-printed text.

3. Submitted material must include a coverage of a topical subject, research methods, results, and review.

Authors of the scientific-research works must indicate the number of experimental biological species drawn in, list the employed methods of anesthetization and soporific means used during acute tests.

4. Articles must have a short (half page) abstract in English, Russian and Georgian (including the following sections: aim of study, material and methods, results and conclusions) and a list of key words.

5. Tables must be presented in an original typed or computer-printed form, instead of a photocopied version. **Numbers, totals, percentile data on the tables must coincide with those in the texts of the articles.** Tables and graphs must be headed.

6. Photographs are required to be contrasted and must be submitted with doubles. Please number each photograph with a pencil on its back, indicate author's name, title of the article (short version), and mark out its top and bottom parts. Drawings must be accurate, drafts and diagrams drawn in Indian ink (or black ink). Photocopies of the X-ray photographs must be presented in a positive image in **tiff format**.

Accurately numbered subtitles for each illustration must be listed on a separate sheet of paper. In the subtitles for the microphotographs please indicate the ocular and objective lens magnification power, method of coloring or impregnation of the microscopic sections (preparations).

7. Please indicate last names, first and middle initials of the native authors, present names and initials of the foreign authors in the transcription of the original language, enclose in parenthesis corresponding number under which the author is listed in the reference materials.

8. Please follow guidance offered to authors by The International Committee of Medical Journal Editors guidance in its Uniform Requirements for Manuscripts Submitted to Biomedical Journals publication available online at: http://www.nlm.nih.gov/bsd/uniform_requirements.html
http://www.icmje.org/urm_full.pdf

In GMN style for each work cited in the text, a bibliographic reference is given, and this is located at the end of the article under the title "References". All references cited in the text must be listed. The list of references should be arranged alphabetically and then numbered. References are numbered in the text [numbers in square brackets] and in the reference list and numbers are repeated throughout the text as needed. The bibliographic description is given in the language of publication (citations in Georgian script are followed by Cyrillic and Latin).

9. To obtain the rights of publication articles must be accompanied by a visa from the project instructor or the establishment, where the work has been performed, and a reference letter, both written or typed on a special signed form, certified by a stamp or a seal.

10. Articles must be signed by all of the authors at the end, and they must be provided with a list of full names, office and home phone numbers and addresses or other non-office locations where the authors could be reached. The number of the authors (co-authors) must not exceed the limit of 5 people.

11. Editorial Staff reserves the rights to cut down in size and correct the articles. Proof-sheets are not sent out to the authors. The entire editorial and collation work is performed according to the author's original text.

12. Sending in the works that have already been assigned to the press by other Editorial Staffs or have been printed by other publishers is not permissible.

**Articles that Fail to Meet the Aforementioned
Requirements are not Assigned to be Reviewed.**

ავტორთა საქურაღებოლ!

რედაქციაში სტატიის წარმოდგენისას საჭიროა დაიცვათ შემდეგი წესები:

1. სტატია უნდა წარმოადგინოთ 2 ცალად, რუსულ ან ინგლისურ ენებზე დაბეჭდილი სტანდარტული ფურცლის 1 გვერდზე, 3 სმ სიგანის მარცხენა ველისა და სტრიქონებს შორის 1,5 ინტერვალის დაცვით. გამოყენებული კომპიუტერული შრიფტი რუსულ და ინგლისურენოვან ტექსტებში - **Times New Roman (Кириллица)**, ხოლო ქართულენოვან ტექსტში საჭიროა გამოვიყენოთ **AcadNusx**. შრიფტის ზომა – 12. სტატიას თან უნდა ახლდეს CD სტატიით.

2. სტატიის მოცულობა არ უნდა შეადგენდეს 10 გვერდზე ნაკლებს და 20 გვერდზე მეტს ლიტერატურის სიის და რეზიუმეების (ინგლისურ, რუსულ და ქართულ ენებზე) ჩათვლით.

3. სტატიაში საჭიროა გაშუქდეს: საკითხის აქტუალობა; კვლევის მიზანი; საკვლევი მასალა და გამოყენებული მეთოდები; მიღებული შედეგები და მათი განსჯა. ექსპერიმენტული ხასიათის სტატიების წარმოდგენისას ავტორებმა უნდა მიუთითონ საექსპერიმენტო ცხოველების სახეობა და რაოდენობა; გაუტკივარებისა და დაძინების მეთოდები (მწვავე ცდების პირობებში).

4. სტატიას თან უნდა ახლდეს რეზიუმე ინგლისურ, რუსულ და ქართულ ენებზე არანაკლებ ნახევარი გვერდის მოცულობისა (სათაურის, ავტორების, დაწესებულების მითითებით და უნდა შეიცავდეს შემდეგ განყოფილებებს: მიზანი, მასალა და მეთოდები, შედეგები და დასკვნები; ტექსტუალური ნაწილი არ უნდა იყოს 15 სტრიქონზე ნაკლები) და საკვანძო სიტყვების ჩამონათვალი (key words).

5. ცხრილები საჭიროა წარმოადგინოთ ნაბეჭდი სახით. ყველა ციფრული, შემაჯამებელი და პროცენტული მონაცემები უნდა შეესაბამებოდეს ტექსტში მოყვანილს.

6. ფოტოსურათები უნდა იყოს კონტრასტული; სურათები, ნახაზები, დიაგრამები - დასათაურებული, დანომრილი და სათანადო ადგილას ჩასმული. რენტგენოგრამების ფოტოასლები წარმოადგინეთ პოზიტიური გამოსახულებით **tiff** ფორმატში. მიკროფოტოსურათების წარწერებში საჭიროა მიუთითოთ ოკულარის ან ობიექტივის საშუალებით გადიდების ხარისხი, ანათალების შედეგის ან იმპრეგნაციის მეთოდი და აღნიშნოთ სურათის ზედა და ქვედა ნაწილები.

7. სამამულო ავტორების გვარები სტატიაში აღინიშნება ინიციალების თანდართვით, უცხოურისა – უცხოური ტრანსკრიპციით.

8. სტატიას თან უნდა ახლდეს ავტორის მიერ გამოყენებული სამამულო და უცხოური შრომების ბიბლიოგრაფიული სია (ბოლო 5-8 წლის სიღრმით). ანბანური წყობით წარმოდგენილ ბიბლიოგრაფიულ სიაში მიუთითეთ ჯერ სამამულო, შემდეგ უცხოელი ავტორები (გვარი, ინიციალები, სტატიის სათაური, ჟურნალის დასახელება, გამოცემის ადგილი, წელი, ჟურნალის №, პირველი და ბოლო გვერდები). მონოგრაფიის შემთხვევაში მიუთითეთ გამოცემის წელი, ადგილი და გვერდების საერთო რაოდენობა. ტექსტში კვადრატულ ფხიხლებში უნდა მიუთითოთ ავტორის შესაბამისი N ლიტერატურის სიის მიხედვით. მიზანშეწონილია, რომ ციტირებული წყაროების უმეტესი ნაწილი იყოს 5-6 წლის სიღრმის.

9. სტატიას თან უნდა ახლდეს: ა) დაწესებულების ან სამეცნიერო ხელმძღვანელის წარდგინება, დამოწმებული ხელმოწერითა და ბეჭდით; ბ) დარგის სპეციალისტის დამოწმებული რეცენზია, რომელშიც მითითებული იქნება საკითხის აქტუალობა, მასალის საკმაობა, მეთოდის სანდოობა, შედეგების სამეცნიერო-პრაქტიკული მნიშვნელობა.

10. სტატიის ბოლოს საჭიროა ყველა ავტორის ხელმოწერა, რომელთა რაოდენობა არ უნდა აღემატებოდეს 5-ს.

11. რედაქცია იტოვებს უფლებას შეასწოროს სტატია. ტექსტზე მუშაობა და შეჯერება ხდება საავტორო ორიგინალის მიხედვით.

12. დაუშვებელია რედაქციაში ისეთი სტატიის წარდგენა, რომელიც დასაბეჭდად წარდგენილი იყო სხვა რედაქციაში ან გამოქვეყნებული იყო სხვა გამოცემებში.

აღნიშნული წესების დარღვევის შემთხვევაში სტატიები არ განიხილება.

Teona Avaliani, Nino Kiria, Nino Bablshvili, Giorgi Pichkhaia, Lali Sharvadze, Nana Kiria. USAGE OF SILVER NANOPARTICLES TO RESTORE MOXIFLOXACIN EFFICACY FOR FLUOROQUINOLONE-RESISTANT M.TUBERCULOSIS CULTURES.....	6-12
Kien Tran, Hung Kieu Dinh, Ha Duong Dai, Tan Hoang Minh, Van Hoang thi Hong, Trang Nguyen Thi Huyen, Mai Bui Thi. EFFECTIVENESS IN INDIRECT DECOMPRESSION USING MINIMALLY INVASIVE SURGERY – TRANSFORAMINAL LUMBAR INTERBODY FUSION IN SINGLE-LEVEL LUMBOSACRAL SPONDYLOLISTHESIS.....	13-18
Yuriy Prudnikov, Olha Yuryk, Mykhailo Sosnov, Anatoliy Stashkevych, Stepan Martsyniak. USE OF ARTIFICIAL INTELLIGENCE IN THE DIAGNOSIS AND TREATMENT OF ORTHOPEDIC DISEASES: LITERATURE REVIEW.....	19-31
Blerta Latifi-Xhemajli. EFFECTIVENESS OF XYLITOL TOOTHPASTE IN CARIES PREVENTION: A REVIEW ARTICLE.....	32-35
Bukia Nato, Machavariani Lamara, Butskhrikidze Marina, Svanidze Militsa, Siradze Mariam. ELECTROMAGNETIC STIMULATION REGULATES BLOOD CORTICOSTERONE LEVELS IN IMMOBILIZED RATS: GENDER DIFFERENCES.....	36-41
Arnab Sain, Urvashi Ghosh, Jack Song Chia, Minaal Ahmed Malik, Nauman Manzoor, Michele Halasa, Fahad Hussain, Hamdoon Asim, Kanishka Wattage, Hoosai Manyar, Ahmed Elkilany, Anushka Jindal, Justin Wilson, Nadine Khayyat, Hannah Burton, Wilam Ivanga Alfred, Vivek Deshmukh, Zain Sohail, Nirav Shah. RECENT TRENDS IN THE USE OF CELL SALVAGER FOR ORTHOPAEDIC TRAUMA AND ELECTIVE SURGERIES-A NARRATIVE REVIEW.....	42-44
Yu.V. Boldyreva, D.G. Gubin, I.A. Lebedev, E.V. Zakharchuk, I.V. Pashkina. ANALYSIS OF BLOOD PARAMETERS IN TYUMEN RESIDENTS WITH COVID-19 IN CATAMNESIS AND/OR VACCINATED AGAINST A NEW CORONAVIRUS INFECTION.....	45-48
Abuova Zh.Zh, Buleshov M.A, Zhaksybergenov A.M, Assilbekova G, Mailykaraeva A.A. THE STUDY OUTCOMES OF THE NEGATIVE IMPACT OF HEXACHLOROCYCLOHEXANE ON VEGETOVASCULAR REGULATION OF NEWBORNS' CARDIAC RHYTHM.....	49-56
Rostomov Faizo E, Sashkova Angelina E, Kruglikov Nikita S, Postnova Elina V, Nasirov Said F.O, Barinova Olga V, Repina Anastasiia F, Kozokova Farida A, Abdulmanatov Magomedemin K, Dzhamalova Asiiat M. THE ROLE OF PSYCHOLOGICAL STRESS IN THE DEVELOPMENT OF ESSENTIAL ARTERIAL HYPERTENSION IN ELDERLY PEOPLE.....	57-59
Hamdoon Asim, Arnab Sain, Nauman Manzoor, Marium Nausherwan, Minaal Ahmed Malik, Fahad Hussain, Mohammad Bilal, Haris Khan, Amir Varasteh, Anushka Jindal, Mohammad Zain Sohail, Nadine Khayyat, Kanishka Wattage, Michele Halasa, Jack Song Chia, Justin Wilson. THE PREVALENCE OF SARCOPENIA AND ITS EFFECTS ON OUTCOMES IN POLYTRAUMA.....	60-65
Sergo Kobalava, Mikheil Tsvetava, Eteri Tsetskhladze. CHRONIC HEART FAILURE WITH PRESERVED LEFT VENTRICLE EJECTION FRACTION (HFPEF) AND RIGHT VENTRICLE INVOLVEMENT IN PATIENTS WITH NORMAL SINUS RHYTHM AND ATRIAL FIBRILLATION; A SMALL OBSERVATIONAL STUDY: RELEVANCE OF THE PROBLEM, DIAGNOSTIC APPROACH, ECHOCARDIOGRAPHIC EVALUATION OF RIGHT VENTRICLE.....	66-74
Sergey V. Osminin, Fedor P. Vetshev, Ildar R. Bilyalov, Marina O. Astaeva, Yevgeniya V. Yeventyeva. PERIOPERATIVE FLOT CHEMOTHERAPY FOR GASTRIC CANCER: A RETROSPECTIVE SINGLE-CENTER COHORT TRIAL.....	75-81
Iskandar M. Alardi, Abbas AA. Kadhim, Ali SM. Aljanabi. PERONEUS LONGUS (PL) AUTOGRAFT IN ANTERIOR CRUCIATE LIGAMENT RECONSTRUCTION AS ALTERNATIVE GRAFT OPTION.....	82-84
Chayakova Akerke, Aiman Musina, Aldanysh Akbolat. TRENDS IN EMERGENCY MEDICAL CALLS BEFORE AND AFTER COVID-19 IN KAZAKHSTAN.....	85-91
Lipatov K.V, Komarova E.A, Solov'eva E.I, Kazantsev A.D, Gorbacheva I.V, Sotnikov D.N, Voinov M.A, Avdienko E.V, Shevchuk A.S, Sarkisyan I.P. MORE ON DEEP HEMATOMAS IN PATIENTS WITH COVID-19: CASE SERIES.....	92-99
Ling-Ling Zhou, Chu-Ying Gao, Jing-Jin Yang, Yong Liang, Lian-Ping He. CURRENT SITUATION AND COUNTERMEASURES OF TALENT TEAM CONSTRUCTION IN THE FIELD OF GRASSROOTS PUBLIC HEALTH.....	100-103
Arnab Sain, Urvashi Ghosh, Michele Halasa, Minaal Ahmed Malik, Nauman Manzoor, Jack Song Chia, Hamdoon Asim, Nadine Khayyat, Kanishka Wattage, Hoosai Manyar, Ahmed Elkilany, Anushka Jindal, Justin Wilson, Fahad Hussain, Hannah Burton, Wilam Ivanga Alfred, Vivek Deshmukh, Zain Sohail, Nirav Shah. USE OF TANTALUM CUP IN TOTAL HIP ARTHROPLASTY-A NARRATIVE REVIEW.....	104-106

Oula E. Hadi, Eman Hashim Yousif. HISTOLOGICAL EXAMINATION OF THE EFFECT OF URANIUM ON UDDER CELLS.....	107-115
Tchernev G, Pidakev I, Lozev I, Warbev M, Ivanova V, Broshtilova V. DERMATOLOGIC SURGERY: ROTATION ADVANCEMENT FLAP AS FIRST LINE TREATMENT FOR HIGH-RISK SQUAMOUS CELL CARCINOMAS OF THE PERIOCLAR/PERIORBITAL ZONE- PRESENTATION AND DISCUSSION ABOUT 2 NEW CASES.....	116-121
Osmalina M.K, Podchernyaeva N.S, Khachatryan L.G, Shpionkova O.V, Velikoretskaya M.D, Chebysheva S. N, Polyanskaya A.V, Gugueva E. A. STROKE AS A LIFE-THREATENING COMPLICATION IN CHILDREN WITH LINEAR SCLERODERMA OF FACE.....	122-128
D. Elgandashvili, Al. Kalantarov, T. Gugeshashvili. MAYER–ROKITANSKY–KUSTER–HAUSER SYNDROME. LAPAROSCOPIC SIGMOID VAGINOPLASTY FOR THE TREATMENT OF VAGINAL AGENESIS - SINGLE CENTER EXPERIENCE IN GEORGIA-CASE REPORT.....	129-138
Gocha Chankseliani, Merab Kiladze, Avtandil Girdaladze, Omar Gibradze. SUCCESSFUL EMERGENCY ARTERIAL EMBOLIZATION FOR MASSIVE GASTRODUODENAL BLEEDING IN HIGH-RISK PATIENT: CASE REPORT.....	139-142
Dildar MM. Mostafa, Mohammed T. Rasool. PREVALENCE OF OSTEOPOROSIS IN PATIENTS WITH RHEUMATOID ARTHRITIS IN IRAQI KURDISTAN /DUHOK GOVERNORATE.....	143-148
Arustamyan Makich, Guseynova Susanna V, Tyulekbayeva Diana, Tkhakokhova Liana A, Krivosheeva Yana V, Vasilev Semen A, Abbasova Zeinab I, Ponomareko Nadezhda O, Ismailova Sabina Z, Zakaev Israpil I. COMPARATIVE ANALYSIS OF HEPATOPROTECTORS IN WISTAR RATS WITH EXPERIMENTALLY INDUCED METABOLICALLY ASSOCIATED FATTY LIVER DISEASE.....	149-150
Jin Wu, Lan-Xi Wu, Kun Yan, Jun-You Li, Tao-Xiang Niu. ALOPECIA AREATA PROFILING SHOWS LNCRNAs REGULATE THE SUPPRESSED EXPRESSION OF KERATIN.....	151-159
Chkhaidze B, Loria L. EVALUATION OF THE FUNCTIONAL CHARACTERISTICS OF THE UNIVERSAL HEALTHCARE PROGRAM BY MEDICAL PERSONNEL IN TBILISI.....	160-164
Osmalina M.K, Podchernyaeva N.S, Khachatryan L.G, Shpionkova O.V, Polyanskaya A.V, Chebysheva S.N, Velikoretskaya M.D. JOINT LESIONS – COMMON EXTRACUTANEOUS MANIFESTATION IN JUVENILE LOCALIZED SCLERODERMA.....	165-172
Haval J. Ali, Zeki A. Mohamed, Dana A. Abdullah. HEALTH-RELATED QUALITY OF LIFE IN CHRONIC MYELOID LEUKAEMIA PATIENTS RECEIVING LONG-TERM THERAPY WITH DIFFERENT TYROSINE KINASE INHIBITORS IN KURDISTAN REGION.....	173-180
Arnab Sain, Ahmed Elkilany, Minaal Ahmed Malik, Nauman Manzoor, Nadine Khayyat, Hoosai Manyar, Michele Halasa, Jack Song Chia, Fahad Hussain, Hamdoon Asim, Kanishka Wattage, Anushka Jindal, Justin Wilson, Hannah Burton, Wilam Ivanga Alfred, Vivek Deshmukh, Zain Sohail. THE USE OF ANKLE BLOCK FOR ACUTE ANKLE FRACTURE REDUCTION: A REVIEW OF CURRENT LITERATURE.....	181-183
Megrelishvili Tamar, Mikadze Ia, Kipiani Nino, Mamuchishvili Nana, Bochorishvili Tea, Imnadze Tamar, Pachkoria Elene, Ratiani Levan. CLINICAL MANIFESTATION AND EPIDEMIOLOGICAL PECULIARITIES OF LEPTOSPIROSIS AT THE MODERN STAGE IN GEORGIA.....	184-187
Raikhan Bekmagambetova, Zulfiya Kachiyeva, Zhanat Ispayeva, Ildar Fakhradiyev, Maia Gotua, Roza Kenzhebekova, Aiganym Tolegenkyzy, Kristina Kovaleva, Gulbarash Turlugulova, Aigerim Zhakiyeva, Nazgul Janabayeva, Kunsulu Rysmakhanova. GENETIC ASSOCIATIONS WITH ASTHMA IN THE KAZAKH POPULATION: A CASE-CONTROL STUDY FOCUSING ON ACTN3 AND TSBP1 POLYMORPHISMS.....	188-194
Farah Saleh Abdul-Reda, Mohammed AH Jabarah AL-Zobaidy. EFFECTIVENESS AND TOLERABILITY OF APREMILAST IN TREATMENT OF A SAMPLE OF PATIENTS WITH PSORIASIS...	195-198
Emma Gevorkyan, Ruzanna Shushanyan, Karine Hovhannisyan, Marietta Karapetyan, Anna Karapetyan. ASSESSMENT OF CHANGES IN HEART RATE VARIABILITY INDICES OF STUDENTS AFTER COVID-19 LOCKDOWN: A COHORT STUDY.....	199-204
Alharbi Badr, Alwashmi Emad, Aloraini Abdullah Saleh, Almanian Ali Ibrahim, Alsuhailani Ali Abdullah, Aloraini Husam Yosuf, Alhwiriny Abdullah Nasser, Altwairgi Adil Khalaf. PERCEPTION OF UROLOGY SPECIALTY AND FACTORS INFLUENCE ITS CONSIDERATION AS A CAREER CHOICE AMONG MEDICALSTUDENTS.....	205-212
Tamuna Dundua, Vladimer Margvelashvili, Manana Kalandadze, Sopia Dalalishvili. THE ORAL HEALTH STATUS AND PREVENTIVE MEASUREMENTS FOR CANCER PATIENTS.....	213-217

SUCCESSFUL EMERGENCY ARTERIAL EMBOLIZATION FOR MASSIVE GASTRODUODENAL BLEEDING IN HIGH-RISK PATIENT: CASE REPORT

Gocha Chankseliani¹, Merab Kiladze¹, Avtandil Girdaladze¹, Omar Gibradze².

¹I. Javakhishvili Tbilisi State University, Faculty of Medicine, Tbilisi, Georgia. ²A. Tsereteli State University, Faculty of Medicine, Kutaisi, Georgia.

Abstract.

Massive upper gastrointestinal bleeding still remains a challenge, which can cause serious clinical problems especially in high-risk patients. We present a rare case of patient with complex pathology successfully managed by endovascular treatment. A 78-year-old man with a medical history of chronic bronchitis, several minor strokes, type II diabetes, a 30-year history of smoking, and a family history of cardiovascular disease, presented with severe pain on the left side of his chest radiating to his left arm. Urgent coronary angiography (CAG) revealed subtotal occlusive thrombosis of the proximal right coronary artery (RCA). An immediate percutaneous coronary intervention (PCI) was conducted and after thrombus aspiration, a 4.0 mm × 30 mm drug-eluting stent (JW Medical Systems) was implanted in the proximal RCA. 12 hours after surgical intervention the patient experienced a sudden syncopal episode. Emergency fibrogastrosocopy revealed active gastroduodenal bleeding from a chronic anterior duodenal ulcer measuring 2.0 mm × 1.5 mm. Endoscopic hemostasis failed and due to patient's unfavorable risk factors (hemorrhagic shock, hemodynamic instability, coagulopathy and etc.,) open surgery was considered as a very high-risk procedure according to the Rockall score. As a last and alternative method, the embolization of the gastroduodenal artery was performed via a radial approach, using a hemostatic sponge and embolization coils (Cook Incorporated, USA). The rapid hemostasis was achieved, patient's condition stabilized post-intervention, and he was discharged in satisfactory condition on the 10th day of hospitalization. Our case illustrates that transcatheter arterial embolization is a safe and feasible method of treatment and real alternative to surgery and failed endoscopic approaches especially in complex and high-risk patients.

Key words. Endovascular treatment, gastrointestinal bleeding, embolization.

Introduction.

Massive upper gastrointestinal bleeding still remains a challenge, which can cause serious clinical problems especially in high-risk patients. We present a rare case of patient with complex pathology successfully managed by endovascular treatment.

It is noteworthy that gastrointestinal bleeding occurs more often in the gastroduodenal artery pool [1]. Until today the peptic ulcer disease is recognized as a widespread condition, with its complications posing significant clinical challenges. While the occurrence of uncomplicated ulcers is declining, the rate of complicated ulcers remains unchanged, with bleeding being the most frequent complication [1-3].

In the United States, approximately 25 million people will experience peptic ulcer disease (PUD) in their lifetime [3]. The majority of these cases, more than 90%, are attributed to *Helicobacter pylori* infection, a link identified in 1983 [4,5]. However, 72% of the public still did not recognize this link. To increase awareness of the association between *H. pylori* and PUD among the public and healthcare professionals, along with various federal agencies, academic institutions, and industry partners, launched an awareness and educational campaign. This campaign was launched on October 19-25, 1997, to coincide with National Infection Control Week. Previously, a survey conducted in early 1997 attempted to update the public's understanding of the causes of PUD. The results of the study, detailed in this report, show that only 27% of the public were aware of the link between *H. pylori* infection and PUD [6]. Part of the Supplemental Health Style Survey, conducted from March to April 1997, Questionnaires were administered to a representative sample of 3,064 US adults aged 18 and older. Participants rated statements about PUD causes and could agree with multiple causes. To correct for variation in response rates among different demographic groups, data were adjusted to reflect the distribution of the US population in 1992 by age, sex, race/ethnicity, income, and region [7]. Peptic ulcers bleeding accounted still today for 40%-50% of all causes of acute upper gastrointestinal bleeding (UGIB) with significant rate of morbidity and mortality.

Our objective was to demonstrate the feasibility and safety of using the arterial embolization method of treatment as alternative to open surgery in complex and high-risk patients.

Case Report.

A 78-year-old male presented with a complex medical history, including osteoporosis, chronic pain managed with NSAIDs and glucocorticoids, hypertension, chronic bronchitis, multiple lacunar cerebral infarctions, and Type II diabetes mellitus (since 2011). The patient was also used Rivaroxaban 20 mg once a day, Actrapid 8-10 IU and Lantus 10 units once daily. He had a 20-year smoking history and a family history of cardiovascular disease, presented with severe pain on the left side of his chest radiating to his left arm. Urgent coronary angiography (CAG) revealed subtotal occlusive thrombosis of the proximal right coronary artery (RCA) (Figure 1). An immediate percutaneous coronary intervention (PCI) was conducted and after thrombus aspiration, a 4.0 mm × 30 mm drug-eluting stent (JW Medical Systems) was implanted in the proximal RCA (Figure 2).

12 hours after surgical intervention the patient experienced a sudden syncopal episode and patient had black stools. On laboratory tests, immediate hemoglobin was 50 g/L, hematocrit 12, pulse was 110 b.p.m. and the blood pressure - 70/50 mm Hg.

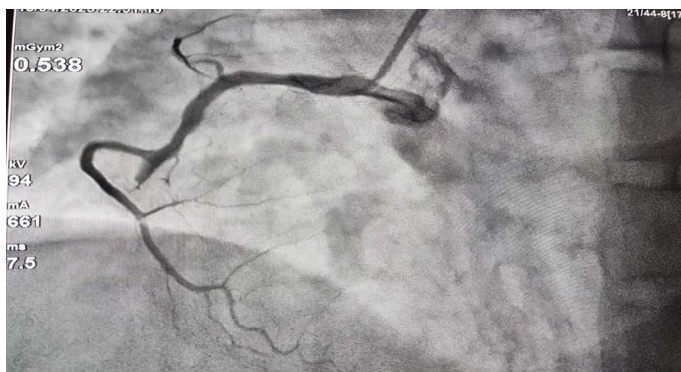

Figure 1. Acute occlusion of the proximal segment of the right artery.

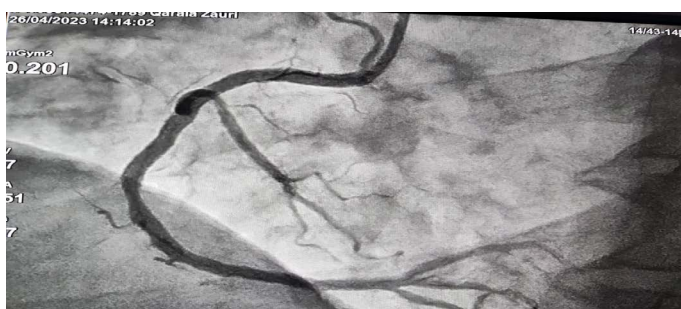

Figure 2. Implanted drug-eluting stent 3.5 mm × 24 mm (JW Medical Systems,) in the proximal RCA.

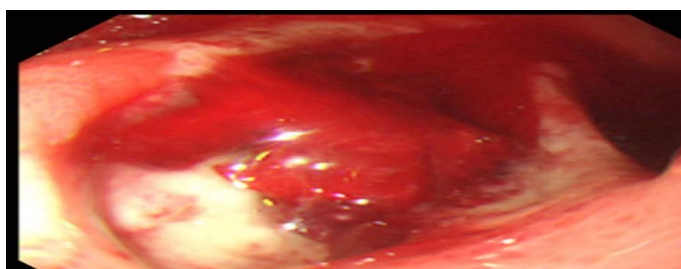


Figure 3. Chronic ulcer of anterior wall of duodenum size 2.0mmx1.5mm covered with Forrest IIA colt.

Due to suspected acute UGIB the emergency fibrogastroscopy was performed, which revealed: a chronic anterior duodenal ulcer measuring 2.0mmx1.5mm covered by a Forrest IIA colt (active stage) with hyperemia of the surrounding mucous membrane (Figure 3). The endoscopic method of treatment failed to stop the patient's bleeding due to the depth of the ulcer and damage to a large-caliber blood vessel. In the intensive care unit (ICU), the patient had bleeding from the NG tube and despite blood transfusion (4 units of blood components), hemoglobin was 60 g/L and hematocrit 12%. Dual antiplatelet therapy was stopped.

A multidisciplinary consultation was convened with the participation of a surgeon, endoscopist, gastroenterologist, anesthesiologist and ICU specialist. Due to the severe condition of the patient and the high risk of postoperative mortality, 8 points according to Rockall score, it was decided to embolize the gastroduodenal artery (GDA), which was performed through a radial approach, using a hemostatic sponge and embolization loops (Cook Incorporated, USA) (Figures 4a-c). The duration between the onset of bleeding and the GDA embolization took 90 minutes.

The patient had no black stools post-intervention after empiric TAE and was stable. No complications were related to ischemia. The antiplatelet treatment was restarted upon hemostasis and after discharge was continued for three months. The patient was discharged on the 10th day of hospitalization. At the last visit, his hemoglobin level was 110 g/L.

Discussion.

The management of massive gastroduodenal bleeding in high-risk patients has always been a complex and critical challenge. Traditionally, the first line of treatment for UGIB has been endoscopic method, which allows for direct visualization of the bleeding site and the application of various hemostatic techniques, such as clipping, injection therapy, and thermal coagulation. Endoscopic treatment is successful in approximately 80-90% of cases, making it a cornerstone in the initial management of UGIB. However, in cases of massive bleeding, anatomical limitations, or poor visualization due to ongoing hemorrhage, endoscopic therapy may fail. This is particularly true when large-caliber vessels such as the gastroduodenal artery are involved, which may not be easily controlled through endoscopic methods [8-10].

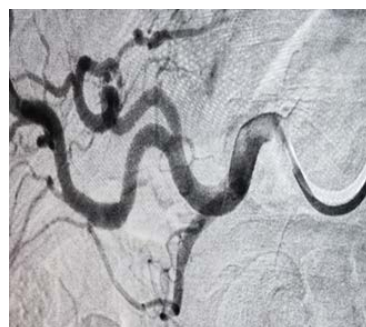


Figure 4A. Angiography.



Figure 4B. Angiography showed active bleeding.

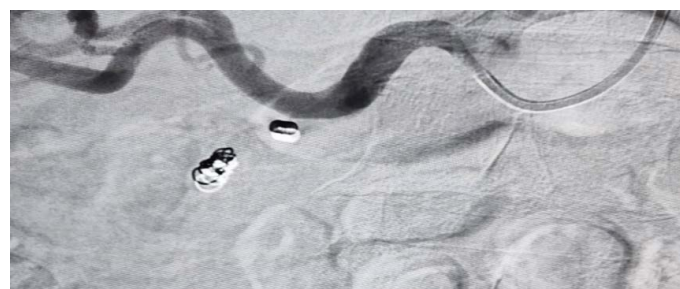

Figure 4C. Complete hemostasis is achieved by closing the GDA.

Given these challenges, alternative approaches that minimize invasiveness while providing effective hemostasis have gained traction in the medical community. Among these, transcatheter arterial embolization (TAE) has emerged as a viable, minimally invasive option for the management of massive gastrointestinal bleeding, especially in patients where surgery poses an unacceptable risk [11,12].

UGIB is a common clinical problem, with an estimated annual incidence ranging from 48 to 160 cases per 100,000 individuals globally. Peptic ulcer disease remains the leading cause of non-variceal UGIB, accounting for up to 50% of cases. The incidence of UGIB increases with age, particularly among patients over the age of 60, due to factors such as the widespread use of nonsteroidal anti-inflammatory drugs (NSAIDs), acetylsalicylic acid (ASA), and the prevalence of comorbidities such as cardiovascular disease and diabetes [13].

Studies have shown that the 30-day mortality rate for UGIB ranges from 5% to 10%, with the highest risk observed in patients with significant comorbidities. The Rockall score (GBS) are commonly used to stratify patients based on their risk of mortality and rebleeding. However, these tools may not fully account for the complexities of managing high-risk patients who may be unsuitable for conventional treatments such as surgery [14].

The increasing prevalence of gastrointestinal bleeding in the context of cardiovascular interventions, such as percutaneous coronary intervention (PCI), further complicates the management of these patients. Antiplatelet therapy, which is essential in preventing stent thrombosis following PCI, significantly increases the risk of gastrointestinal hemorrhage. Discontinuation of antiplatelet therapy in the setting of gastrointestinal bleeding can precipitate life-threatening thrombotic events, creating a delicate balance between preventing bleeding and maintaining antithrombotic therapy [15].

Lower gastrointestinal bleeding is characterized by bleeding from a source beyond the ligaments of Treitz. Approximately 80% of lower gastrointestinal bleeding occurs from colorectal sources, and 5% to 10% from the small intestine. Gastrointestinal bleeding occurs in the remaining 10% to 15% of cases. Bleeding sources in the small intestine are often more difficult to identify than in the colorectal region [16,17]. It is important to know the severity of bleeding according to the Forrest classification, which is important to correctly and strictly define the indication for embolization, which ensures that the relevant results are discussed [18].

Improvements in catheter technology, development of more compatible embolization devices, and expansion of embolization techniques have led to angiography and embolization for the treatment of upper and lower gastrointestinal bleeding [19,20]. Transcatheter embolization is a safe and effective procedure for managing acute gastrointestinal (GI) bleeding, demonstrating high technical success and favourable clinical outcomes. However, it should be considered only after endoscopic and medical interventions have proven ineffective. In stable patients, MDCT imaging plays a crucial role in pinpointing the bleeding site and assessing the gastrointestinal anatomy. Collaboration between surgeons, anesthesiologists, interventional and

diagnostic radiologists and gastroenterologists is vital for the successful treatment of patients with GI bleeding [21,22]. Endovascular embolization significantly lowers the mortality rate in high-risk patients, who require open surgery following failed endoscopic treatment. However, further research is necessary to comprehensively address these outcomes.

Conclusion.

Angiography and embolization have become viable options for the treatment of both upper and lower gastrointestinal bleeding due to advances in catheter technology, more compatible embolization devices, and advanced techniques. For patients, who have not responded to medical management and endoscopic treatment, transcatheter embolization therapy is a safe and highly effective procedure, both technically and clinically. In stable patients, MDCT imaging is valuable for anatomic evaluation of the gastrointestinal tract and for pinpointing the source of bleeding. Optimal patient care relies on close collaboration between interventional and diagnostic radiologists, surgeons and gastroenterologists. Endovascular embolization significantly reduces mortality in high-risk patients requiring open surgery after failed endoscopy. Our case illustrates, that transcatheter arterial embolization is a safe and feasible method of treatment and real alternative to surgery and failed endoscopic approach especially in complex and high-risk patients. However, additional research is needed to fully explore these objectives. The procedure should be considered as a secondary treatment option for those who have not responded to initial interventions.

Ethics approval.

The authors are accountable for all aspects of the work in ensuring that questions related to the accuracy or integrity of any part of the work are appropriately investigated and resolved. Written informed consent was obtained from the patient for publication of these Images. Board institutional approval was not required.

Declaration of competing interest.

The authors declare no competing interests.

Funding.

This study was not supported by any sponsor or funder.

REFERENCES

1. Shim J.J, Chu HH, Shin JH, et al. Clinical Outcome of the Visible Coil During Endoscopy After Transcatheter Arterial Embolization for Gastrointestinal Bleeding. *Cardiovasc Intervent Radiol.* 2019;42:1537-1544.
2. Rao K.A, Al-Hakim R, Scagnelli T, et al. Gastroduodenal artery coiling to curb upper gastrointestinal bleeding. *J Pediatr Surg.* 2017;52:1699-1701.
3. Barkun A. N. International Consensus Recommendations on the Management of Patients With Nonvariceal Upper Gastrointestinal Bleeding. *Ann Intern Med.* 2010;152:101.
4. Loffroy R, Comby PO, Falvo N. Transcatheter arterial embolization versus surgery for uncontrolled peptic ulcer bleeding: game is over. *Quant Imaging Med Surg.* 2019;9:144-145.

5. Sheth R, Someshwar V, Warawdekar G. Treatment of acute lower gastrointestinal hemorrhage by superselective transcatheter embolization. *Indian J Gastroenterol.* 2006;25:290-294.
6. Mirsadraee S, Tirukonda P, Nicholson A. Embolization for non-variceal upper gastrointestinal tract haemorrhage: A systematic review. *Clin Radiol.* 2011;66:500-509.
7. Ahmad F. B, Cisewski J. A, Xu J, et al. Provisional Mortality Data - United States, 2022. *MMWR Morb Mortal Wkly Rep.* 2023;72:488-492.
8. Centers for Disease Control and Prevention (CDC). Knowledge about causes of peptic ulcer disease -- United States, March-April 1997. *MMWR Morb Mortal Wkly Rep.* 1997;46:985-987.
9. Feinstein L.B, Holman R.C, Yorita Christensen K.L, et al. Trends in hospitalizations for peptic ulcer disease, United States, 1998-2005. *Emerg Infect Dis.* 2010;16:1410-1418.
10. Kyaw M, Tse Y, Ang D, et al. Embolization versus surgery for peptic ulcer bleeding after failed endoscopic hemostasis: a meta-analysis. *Endosc Int Open.* 2014;2:E6-E14.
11. Loffroy R, Guiu B. Role of transcatheter arterial embolization for massive bleeding from gastroduodenal ulcers. *World J Gastroenterol.* 2009;15:5889-97.
12. Chankseliani G, Girdaladze A, Gibradze O, et al. The features of endovascular surgery for duodenal ulcer bleeding. *World Science.* 2023;4.
13. Gralnek I.M, Dumonceau J.M, Kuipers E.J. Diagnosis and management of nonvariceal upper gastrointestinal hemorrhage: European Society of Gastrointestinal Endoscopy (ESGE) Guideline. *Endoscopy.* 2015;47:a1-46.
14. Loffroy R, Comby P.O, Falvo N. Transcatheter arterial embolization versus surgery for uncontrolled peptic ulcer bleeding: game is over. *Quant Imaging Med Surg.* 2019;9:144-145.
15. Wu R, Li J, Guo Y. Treatment of acute upper gastrointestinal bleeding occurred after percutaneous coronary intervention for acute myocardial infarction in patients with acute renal impairment: a case report. *Cardiovasc Endocrinol Metab.* 2022;11:e0269.
16. Spiliopoulos S, Inchingolo R, Lucatelli P, et al. Transcatheter Arterial Embolization for Bleeding Peptic Ulcers: A Multicenter Study. *Cardiovasc Intervent Radiol.* 2018;41:1333-1339.
17. Tarasconi A, Baiocchi GL, Pattonieri V. Transcatheter arterial embolization versus surgery for refractory non-variceal upper gastrointestinal bleeding: a meta-analysis. *World J Emerg Surg.* 2019;14:3.
18. Rao KA, Al-Hakim R, Scagnelli T. Gastroduodenal artery coiling to curb upper gastrointestinal bleeding. *J Pediatr Surg.* 2017;52:1699-1701.
19. Loffroy R, Lin M, Thompson C. A comparison of the results of arterial embolization for bleeding and non-bleeding gastroduodenal ulcers. *Acta Radiol.* 2011;52:1076-82.
20. Gralnek IM, Dumonceau JM, Kuipers EJ, et al. Diagnosis and management of nonvariceal upper gastrointestinal hemorrhage: European Society of Gastrointestinal Endoscopy (ESGE) Guideline. *Endoscopy.* 2015;47:a1-46.
21. Loffroy R, Favelier S, Pottecher P. Transcatheter arterial embolization for acute nonvariceal upper gastrointestinal bleeding: Indications, techniques and outcomes. *Diagn Interv Imaging.* 2015;96:731-744.
22. Pang S.H, Ching JYL, Lau JYW, et al. Comparing the Blatchford and pre-endoscopic Rockall score in predicting the need for endoscopic therapy in patients with upper GI hemorrhage. *Gastrointest Endosc.* 2010;71:1134-1140.